



National Comprehensive  
Cancer Network®


NCCN Clinical Practice Guidelines in Oncology (NCCN Guidelines®)

# Squamous Cell Skin Cancer

**NCCN Evidence Blocks™**

Version 1.2020 — October 2, 2019

[NCCN.org](https://www.nccn.org)



[Continue](#)



National  
Comprehensive  
Cancer  
Network®

# NCCN Guidelines Version 1.2020

## Squamous Cell Skin Cancer

### NCCN Evidence Blocks™

[NCCN Guidelines Index](#)  
[Table of Contents](#)  
[Discussion](#)

**Chrysalyn D. Schmuts, MD/Chair** ∞ ¶  
Dana-Farber/Brigham and Women's  
Cancer Center

**Rachel Blitzblau, MD, PhD/Vice Chair** §  
Duke Cancer Institute

**Sumaira Z. Aasi, MD** ∞  
Stanford Cancer Institute

**Murad Alam, MD** ∞ ¶ §  
Robert H. Lurie Comprehensive Cancer  
Center of Northwestern University

**James S. Andersen, MD** ¶ Ÿ  
City of Hope National Medical Center

**Jeremy Bordeaux, MD, MPH** ∞  
Case Comprehensive Cancer Center/  
University Hospitals Seidman Cancer  
Center and Cleveland Clinic Taussig  
Cancer Institute

**Glen M. Bowen, MD** ∞  
Huntsman Cancer Institute  
at the University of Utah

**William Carson III, MD** ¶  
The Ohio State University Comprehensive  
Cancer Center - James Cancer Hospital  
and Solove Research Institute

**Pei-Ling Chen, MD, PhD** ≠  
Moffitt Cancer Center

**Carlo M. Contreras, MD** ¶  
O'Neal Comprehensive Cancer Center at UAB

**Mackenzie Daly, MD** §  
Siteman Cancer Center at Barnes-  
Jewish Hospital and Washington  
University School of Medicine

**Gregory A. Daniels, MD, PhD** † ≠ ¶  
UC San Diego Moores Cancer Center

**Dominick DiMaio, MD** ≠  
Fred & Pamela Buffett Cancer Center

**Jeffrey M. Farma, MD** ¶  
Fox Chase Cancer Center

**Kristopher Fisher, MD** ∞ ≠  
St. Jude Children's Research Hospital/  
University of Tennessee Health Science Center

**Karthik Ghosh, MD** ¶  
Mayo Clinic Cancer Center

**Roy C. Grekin, MD** ∞ ¶  
UCSF Helen Diller Family  
Comprehensive Cancer Center

**Kelly Harms, MD, PhD** ∞  
University of Michigan Rogel Cancer Center

**Alan L. Ho, MD, PhD** †  
Memorial Sloan Kettering Cancer Center

**Donald Lawrence, MD** †  
Massachusetts General Hospital Cancer Center

**Karl D. Lewis, MD** †  
University of Colorado Cancer Center

**Manisha Loss, MD** ∞  
Sidney Kimmel Comprehensive  
Cancer Center at Johns Hopkins

**John Nicholas Lukens, MD** §  
Abramson Cancer Center at the  
University of Pennsylvania

**Kishwer S. Nehal, MD** ∞ ¶  
Memorial Sloan Kettering Cancer Center

**Paul Nghiem, MD, PhD** ∞  
Fred Hutchinson Cancer Research  
Center/Seattle Cancer Care Alliance

**Igor Puzanov, MD, MSCI, FACP** †  
Roswell Park Cancer Institute

**Aleksandar Sekulic, MD, PhD** ∞  
Mayo Clinic Cancer Center

**Ashok R. Shaha, MD** ¶ §  
Memorial Sloan Kettering Cancer Center

**William Stebbins, MD** ∞  
Vanderbilt-Ingram Cancer Center

**Valencia Thomas, MD** ∞  
The University of Texas  
MD Anderson Cancer Center

**Yaohui G. Xu, MD, PhD** ∞  
University of Wisconsin  
Carbone Cancer Center

**NCCN**  
**Anita Engh, PhD**  
**Lydia Hammond, MBA**

∞ Dermatology  
¶ Internal medicine  
† Medical oncology  
§ Otolaryngology  
≠ Pathology/Dermatopathology  
Ÿ Reconstructive surgery  
§ Radiotherapy/Radiation oncology  
¶ Surgery/Surgical oncology  
\* Discussion Section Writing Committee

**Continue**

[NCCN Guidelines Panel Disclosures](#)



[NCCN Squamous Cell Skin Cancer Panel Members](#)  
[NCCN Evidence Blocks Definitions \(EB-1\)](#)

[Clinical Presentation, Workup, Diagnosis and Risk Status \(SCC-1\)](#)  
[Treatment for Local, Low-Risk Squamous Cell Skin Cancer \(SCC-2\)](#)  
[Treatment for Local, High-Risk Squamous Cell Skin Cancer \(SCC-3\)](#)  
[Clinical Staging, Preoperative Assessment and Primary Treatment \(SCC-4\)](#)  
[Follow-up \(SCC-6\)](#)

[Principles of Pathology for Squamous Cell Skin Cancer \(SCC-A\)](#)  
[Risk Factors for Local Recurrence or Metastases \(SCC-B\)](#)  
[Identification and Management of High-Risk Patients \(SCC-C\)](#)  
[Principles of Treatment for Squamous Cell Skin Cancer \(SCC-D\)](#)  
[Principles of Radiation Therapy for Squamous Cell Skin Cancer \(SCC-E\)](#)  
[Principles of Systemic Therapy for Squamous Cell Skin Cancer \(SCC-F\)](#)

[Staging \(ST-1\)](#)  
[NCCN Categories of Evidence and Consensus \(CAT-1\)](#)

**Clinical Trials:** NCCN believes that the best management for any patient with cancer is in a clinical trial. Participation in clinical trials is especially encouraged.

To find clinical trials online at NCCN Member Institutions, [click here: nccn.org/clinical\\_trials/member\\_institutions.aspx](#).

**NCCN Categories of Evidence and Consensus:** All recommendations are category 2A unless otherwise indicated.

[See NCCN Categories of Evidence and Consensus.](#)

**NCCN Guidelines for Patients®**  
available at [www.nccn.org/patients](http://www.nccn.org/patients)

The NCCN Guidelines® are a statement of evidence and consensus of the authors regarding their views of currently accepted approaches to treatment. Any clinician seeking to apply or consult the NCCN Guidelines is expected to use independent medical judgment in the context of individual clinical circumstances to determine any patient's care or treatment. The National Comprehensive Cancer Network® (NCCN®) makes no representations or warranties of any kind regarding their content, use or application and disclaims any responsibility for their application or use in any way. The NCCN Evidence Blocks™ and NCCN Guidelines are copyrighted by National Comprehensive Cancer Network®. All rights reserved. The NCCN Evidence Blocks™, NCCN Guidelines, and the illustrations herein may not be reproduced in any form without the express written permission of NCCN. ©2019.



# NCCN Guidelines Version 1.2020

## Squamous Cell Skin Cancer

### NCCN Evidence Blocks™

#### NCCN EVIDENCE BLOCKS CATEGORIES AND DEFINITIONS

5					
4					
3					
2					
1					

**E = Efficacy of Regimen/Agent**  
**S = Safety of Regimen/Agent**  
**Q = Quality of Evidence**  
**C = Consistency of Evidence**  
**A = Affordability of Regimen/Agent**

#### Example Evidence Block

5					
4	■	■		■	
3	■	■	■	■	■
2	■	■	■	■	■
1	■	■	■	■	■

**E = 4**  
**S = 4**  
**Q = 3**  
**C = 4**  
**A = 3**

#### Efficacy of Regimen/Agent

5	<b>Highly effective:</b> Cure likely and often provides long-term survival advantage
4	<b>Very effective:</b> Cure unlikely but sometimes provides long-term survival advantage
3	<b>Moderately effective:</b> Modest impact on survival, but often provides control of disease
2	<b>Minimally effective:</b> No, or unknown impact on survival, but sometimes provides control of disease
1	<b>Palliative:</b> Provides symptomatic benefit only

#### Safety of Regimen/Agent

5	<b>Usually no meaningful toxicity:</b> Uncommon or minimal toxicities; no interference with activities of daily living (ADLs)
4	<b>Occasionally toxic:</b> Rare significant toxicities or low-grade toxicities only; little interference with ADLs
3	<b>Mildly toxic:</b> Mild toxicity that interferes with ADLs
2	<b>Moderately toxic:</b> Significant toxicities often occur but life threatening/fatal toxicity is uncommon; interference with ADLs is frequent
1	<b>Highly toxic:</b> Significant toxicities or life threatening/fatal toxicity occurs often; interference with ADLs is usual and severe

**Note: For significant chronic or long-term toxicities, score decreased by 1**

#### Quality of Evidence

5	<b>High quality:</b> Multiple well-designed randomized trials and/or meta-analyses
4	<b>Good quality:</b> One or more well-designed randomized trials
3	<b>Average quality:</b> Low quality randomized trial(s) or well-designed non-randomized trial(s)
2	<b>Low quality:</b> Case reports or extensive clinical experience
1	<b>Poor quality:</b> Little or no evidence

#### Consistency of Evidence

5	<b>Highly consistent:</b> Multiple trials with similar outcomes
4	<b>Mainly consistent:</b> Multiple trials with some variability in outcome
3	<b>May be consistent:</b> Few trials or only trials with few patients, whether randomized or not, with some variability in outcome
2	<b>Inconsistent:</b> Meaningful differences in direction of outcome between quality trials
1	<b>Anecdotal evidence only:</b> Evidence in humans based upon anecdotal experience

#### Affordability of Regimen/Agent (includes drug cost, supportive care, infusions, toxicity monitoring, management of toxicity)

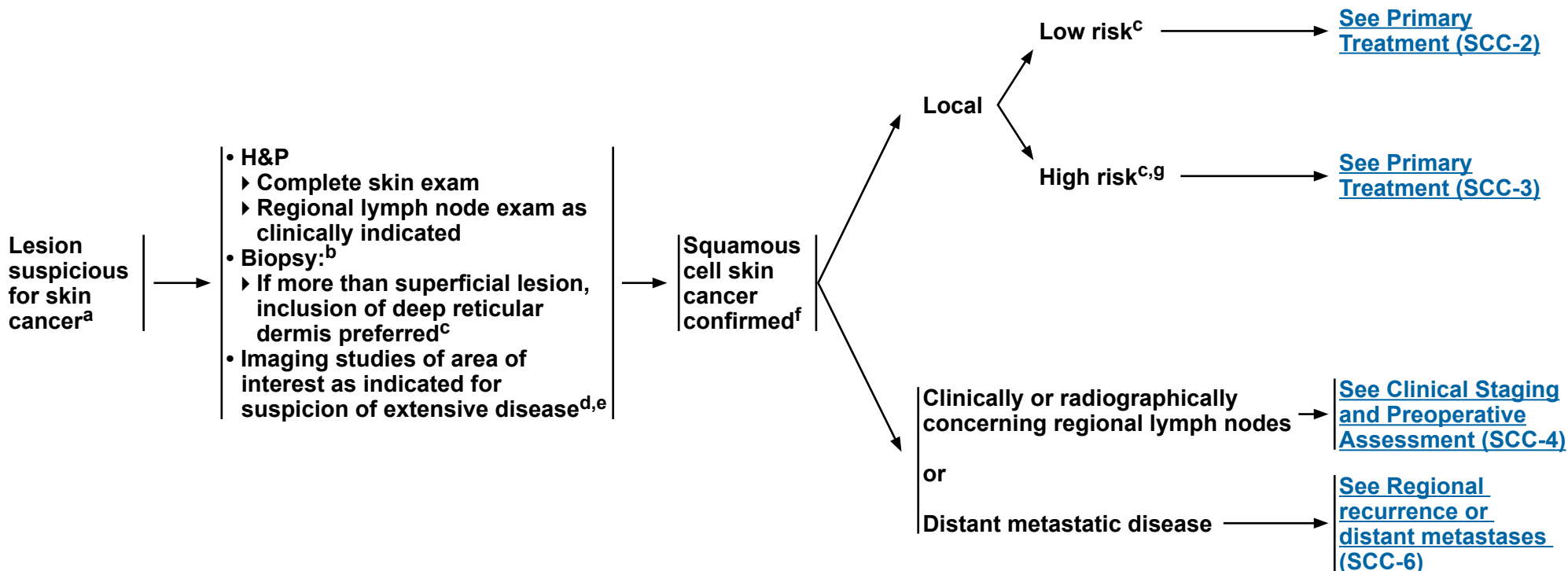
5	<b>Very inexpensive</b>
4	<b>Inexpensive</b>
3	<b>Moderately expensive</b>
2	<b>Expensive</b>
1	<b>Very expensive</b>

**CLINICAL PRESENTATION**

**WORKUP**

**DIAGNOSIS**

**RISK STATUS**



<sup>a</sup> For more information, see American Academy of Dermatology Association: <https://www.aad.org/public/diseases/skin-cancer/squamous-cell-carcinoma>.

<sup>b</sup> See [Principles of Pathology \(SCC-A\)](#).

<sup>c</sup> See [Risk Factors for Local Recurrence or Metastases \(SCC-B\)](#) and [Identification and Management of High-Risk Patients \(SCC-C\)](#).

<sup>d</sup> Extensive disease includes deep structural involvement such as bone, perineural disease, and deep soft tissue. If perineural disease or deep soft tissue involvement is suspected, MRI with contrast is preferred. If bone disease is suspected, CT with contrast is preferred unless contraindicated.

<sup>e</sup> For rare cases that present with distant metastatic disease at diagnosis, treat as distant metastases pathway on [SCC-6](#). Imaging modality and targeted area should be at the discretion of the treating team based on the suspected extent of disease (ie, local, regional, metastatic).

<sup>f</sup> Including squamous cell skin cancer in situ (showing full-thickness epidermal atypia, excluding actinic keratoses).

<sup>g</sup> Any high-risk factor places the patient in the high-risk category.

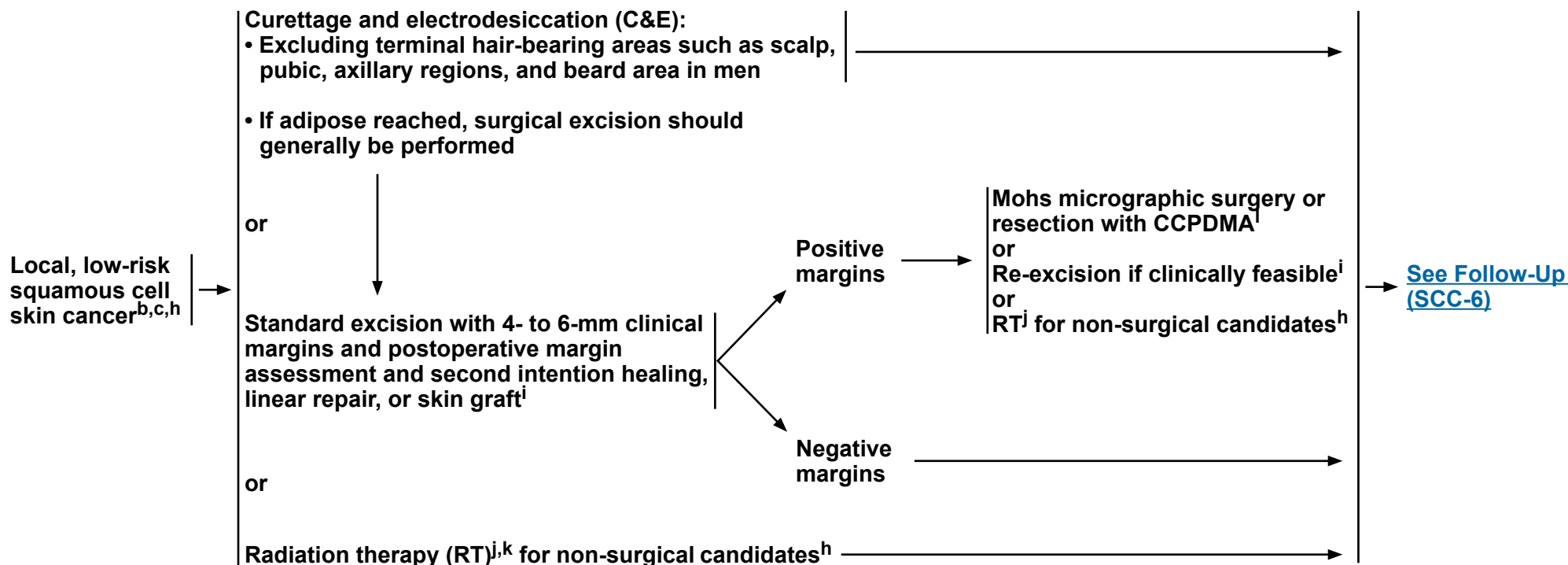
**Note: For more information regarding the categories and definitions used for the NCCN Evidence Blocks™, see page [EB-1](#).**

**All recommendations are category 2A unless otherwise indicated.**

**Clinical Trials: NCCN believes that the best management of any patient with cancer is in a clinical trial. Participation in clinical trials is especially encouraged.**



**PRIMARY TREATMENT<sup>h</sup>**



<sup>b</sup> See Principles of Pathology (SCC-A).

<sup>c</sup> See Risk Factors for Local Recurrence or Metastases (SCC-B) and Identification and Management of High-Risk Patients (SCC-C).

<sup>h</sup> See Principles of Treatment for Squamous Cell Skin Cancer (SCC-D).

<sup>i</sup> Closures like adjacent tissue transfers, in which significant tissue rearrangement occurs, are best performed after clear margins are verified.

<sup>j</sup> See Principles of Radiation Therapy for Squamous Cell Skin Cancer (SCC-E).

<sup>k</sup> RT is often reserved for patients older than 60 years because of concerns about long-term sequelae.

<sup>l</sup> Excision with complete circumferential peripheral and deep margin assessment (CCPDMA) with permanent section analysis or intraoperative frozen section analysis is an alternative to Mohs micrographic surgery.

**Note: For more information regarding the categories and definitions used for the NCCN Evidence Blocks™, see page EB-1.**

**All recommendations are category 2A unless otherwise indicated.**

**Clinical Trials: NCCN believes that the best management of any patient with cancer is in a clinical trial. Participation in clinical trials is especially encouraged.**

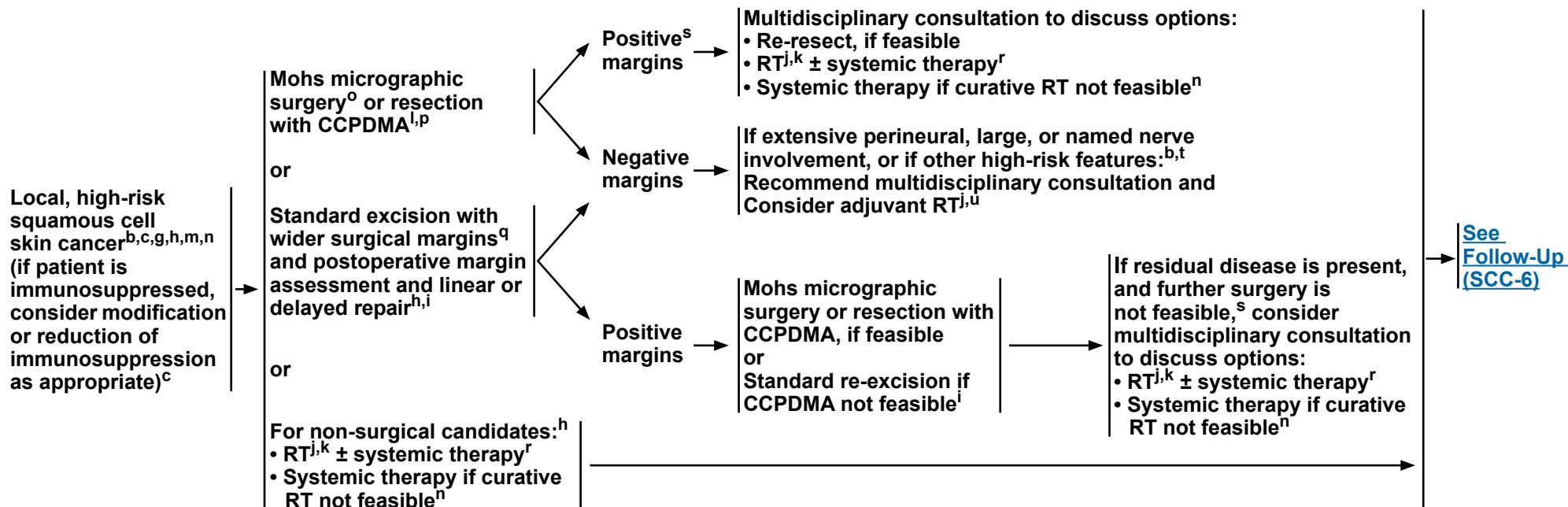


# NCCN Guidelines Version 1.2020

## Squamous Cell Skin Cancer

### NCCN Evidence Blocks™

#### PRIMARY TREATMENT<sup>h</sup>



<sup>b</sup> See [Principles of Pathology \(SCC-A\)](#).

<sup>c</sup> See [Risk Factors for Local Recurrence or Metastases \(SCC-B\)](#) and [Identification and Management of High-Risk Patients \(SCC-C\)](#).

<sup>g</sup> Any high-risk factor places the patient in the high-risk category.

<sup>h</sup> See [Principles of Treatment for Squamous Cell Skin Cancer \(SCC-D\)](#).

<sup>i</sup> Closures like adjacent tissue transfers, in which significant tissue rearrangement occurs, are best performed after clear margins are verified.

<sup>j</sup> See [Principles of Radiation Therapy for Squamous Cell Skin Cancer \(SCC-E\)](#).

<sup>k</sup> RT is often reserved for patients older than 60 years of age because of concerns about long-term sequelae.

<sup>l</sup> Excision with CCPDMA with permanent section analysis or intraoperative frozen section analysis is an alternative to Mohs micrographic surgery.

<sup>m</sup> In certain high-risk lesions, consider sentinel lymph node mapping, although the benefit of and indication for this technique has yet to be proven.

<sup>n</sup> For complicated cases, consider multidisciplinary consultation. For locally advanced disease in which curative RT and curative surgery are not feasible, consider treatment with immunotherapy (cemiplimab-rwlc or clinical trial). See [Principles of Systemic Therapy \(SCC-F\)](#).

<sup>o</sup> When Mohs micrographic surgery with margin assessment is being performed and the preoperative biopsy is considered insufficient for providing all the staging information required to properly treat the tumor, submission of the central specimen for vertical paraffin-embedded permanent sections or documentation of staging parameters in Mohs report is recommended.

<sup>p</sup> If invasion to parotid fascia, superficial parotidectomy is indicated.

<sup>q</sup> Due to the wide variability of clinical characteristics that may define a high-risk tumor, it is not feasible to recommend a defined margin for standard excision of high-risk SCC. Keen awareness of the subclinical extension of SCC is advised when selecting a treatment modality without complete margin assessment for a high-risk tumor. These margins may need to be modified based on tumor or patient-specific factors.

<sup>r</sup> RT may be supplemented by systemic therapy in select patients. See [Principles of Systemic Therapy \(SCC-F\)](#).

<sup>s</sup> Negative margins unachievable by Mohs micrographic surgery or more extensive surgical procedures.

<sup>t</sup> Large nerve involvement is defined by AJCC 8th edition for cutaneous SCC of the head and neck as ≥0.1 mm; most nerves deep to the dermis are >0.1 mm.

<sup>u</sup> The outcome benefit of adjuvant RT following resection of any cutaneous SCC with negative surgical margins is uncertain.

**Note: For more information regarding the categories and definitions used for the NCCN Evidence Blocks™, see page EB-1.**

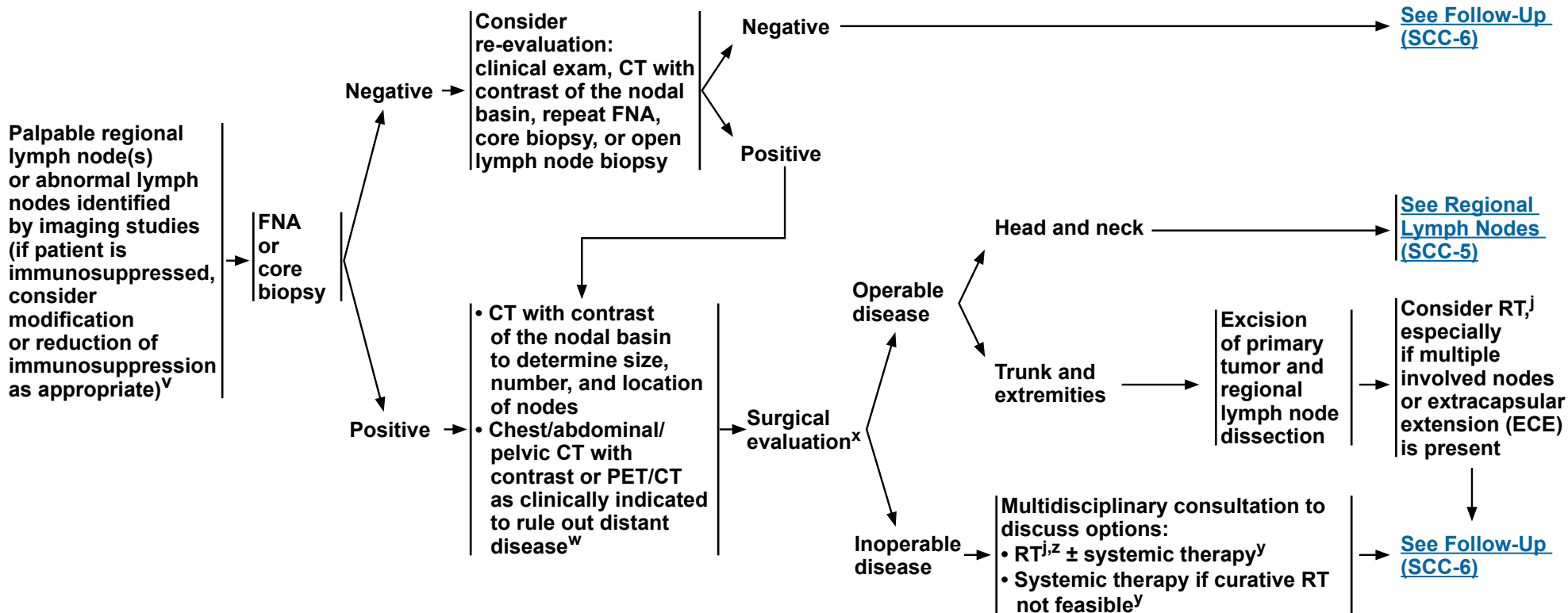
**All recommendations are category 2A unless otherwise indicated.**

**Clinical Trials: NCCN believes that the best management of any patient with cancer is in a clinical trial. Participation in clinical trials is especially encouraged.**



#### CLINICAL STAGING AND PREOPERATIVE ASSESSMENT

#### PRIMARY TREATMENT<sup>h</sup>



<sup>h</sup> See Principles of Treatment for Squamous Cell Skin Cancer (SCC-D).

<sup>j</sup> See Principles of Radiation Therapy for Squamous Cell Skin Cancer (SCC-E).

<sup>v</sup> See Identification and Management of High-Risk Patients (SCC-C).

<sup>w</sup> Based on clinical findings, brain MRI with contrast.

<sup>x</sup> Regional lymph node dissection is preferred unless the patient is not a surgical candidate.

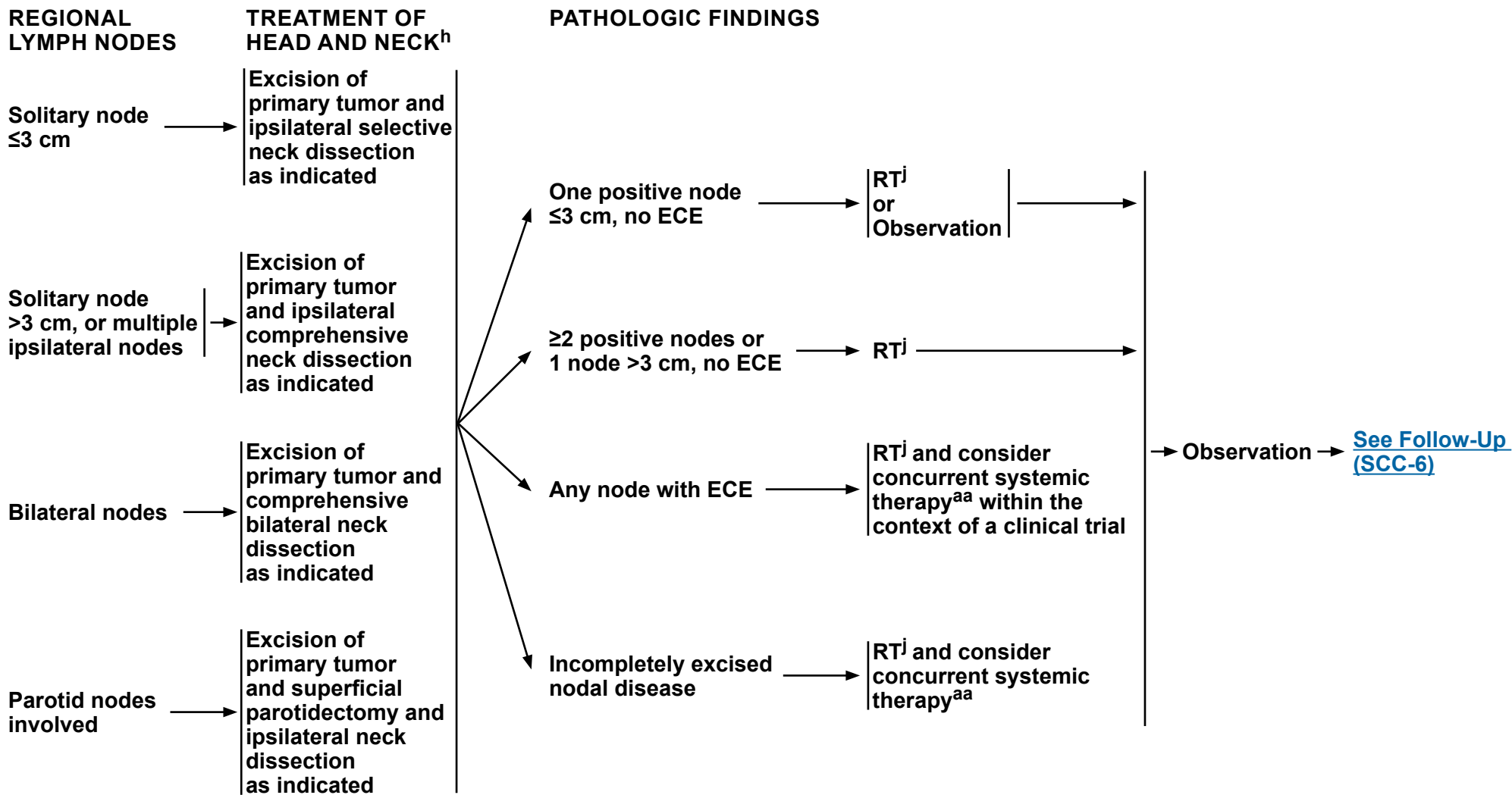
<sup>y</sup> See Principles of Systemic Therapy (SCC-F).

<sup>z</sup> Consider palliative RT/surgery for symptomatic sites. SBRT may also be considered in select patients.

**Note:** For more information regarding the categories and definitions used for the NCCN Evidence Blocks™, see page EB-1.

All recommendations are category 2A unless otherwise indicated.

Clinical Trials: NCCN believes that the best management of any patient with cancer is in a clinical trial. Participation in clinical trials is especially encouraged.



<sup>h</sup> See Principles of Treatment for Squamous Cell Skin Cancer (SCC-D).

<sup>j</sup> See Principles of Radiation Therapy for Squamous Cell Skin Cancer (SCC-E).

<sup>aa</sup> Multidisciplinary consultation recommended. See Principles of Systemic Therapy (SCC-F).

Note: For more information regarding the categories and definitions used for the NCCN Evidence Blocks™, see page EB-1.

All recommendations are category 2A unless otherwise indicated.

Clinical Trials: NCCN believes that the best management of any patient with cancer is in a clinical trial. Participation in clinical trials is especially encouraged.

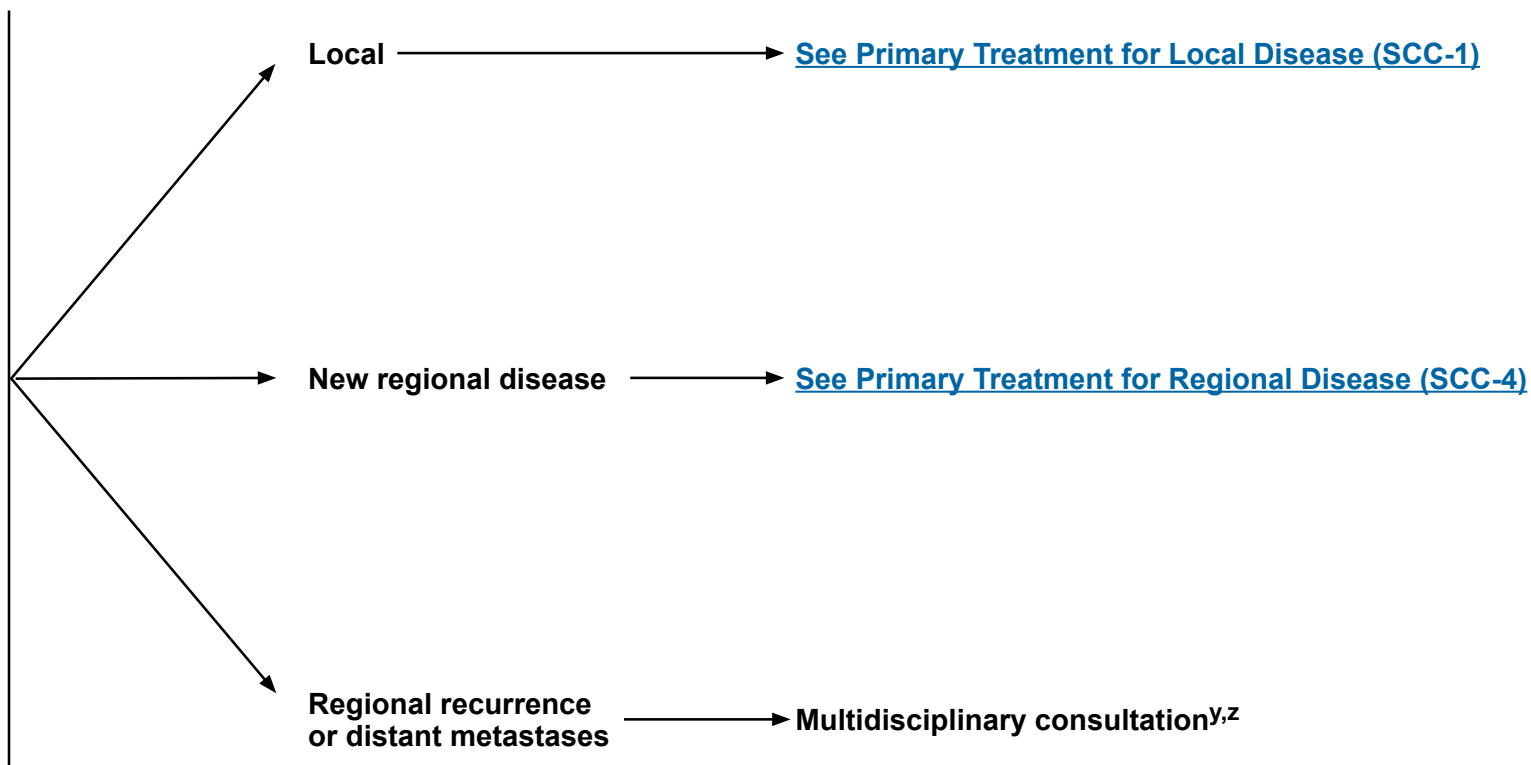
#### FOLLOW-UP

##### Local disease:

- H&P<sup>bb,cc</sup>
  - ▶ Every 3–12 mo for 2 y, then every 6–12 mo for 3 y, then annually for life
- Patient education
  - ▶ Sun protection
  - ▶ Self examination of skin

##### Regional disease:

- H&P<sup>bb,cc,dd</sup>
  - ▶ Every 1–3 mo for 1 y, then every 2–4 mo for 1 y, then every 4–6 mo for 3 y, then every 6–12 mo for life
- Patient education
  - ▶ Sun protection
  - ▶ Self examination of skin and lymph nodes



<sup>y</sup> See Principles of Systemic Therapy (SCC-F).

<sup>z</sup> Consider palliative RT/surgery for symptomatic sites. SBRT may also be considered in select patients.

<sup>bb</sup> Including complete skin and regional lymph node exam.

<sup>cc</sup> Frequency of follow-up should be adjusted based on risk.

<sup>dd</sup> Surveillance CT with contrast of regional nodal basin and to evaluate for distant metastatic disease, ideally based on multidisciplinary board recommendation, or as clinically indicated.

**Note:** For more information regarding the categories and definitions used for the NCCN Evidence Blocks™, see page [EB-1](#).

All recommendations are category 2A unless otherwise indicated.

Clinical Trials: NCCN believes that the best management of any patient with cancer is in a clinical trial. Participation in clinical trials is especially encouraged.

**PRINCIPLES OF PATHOLOGY****Principles of Biopsy Reporting:**

- Pathologic evaluation of skin biopsies is ideally performed by a dermatologist, pathologist, or dermatopathologist who is experienced in interpreting cutaneous neoplasms.
- Clinical information to be submitted on biopsy requisition includes patient demographics, anatomic location, prior treatment of lesion, clinical diameter of lesion, and patient risk factors such as immunosuppression, RT, or organ transplant history.
- The final pathology report should include histologic subtype (if it is one of the specified high- or low-risk types<sup>1</sup>), and presence of any features that would classify the lesion as T2 or above (per AJCC 8th Edition staging), which include tumor diameter >2 cm, depth >6 mm or extension beyond subcutaneous fat, bone erosion, or perineural invasion involving nerve below dermis or >0.1 mm in caliber.<sup>2</sup>
  - ▶ Report histologic grade (degree of cellular differentiation) if possible.
  - ▶ Involvement of deep shave biopsy edge should be noted.

**Principles of Excision Reporting:**

- Saucerization specimens intended for definitive surgical therapy should be labeled as such, as they can be histopathologically difficult to distinguish from shave biopsies but must be evaluated for margin status.
- Clinical information to be submitted on excision requisition includes patient demographics, anatomic location, and clinical diameter of lesion and additional clinical information listed above under biopsy if not previously reported.
- The final pathology report should include histologic subtype (if it is one of the specified high- or low-risk types<sup>1</sup>), presence of angiolymphatic invasion, peripheral and deep margin status, and all features necessary for accurate staging per AJCC 8th Edition staging,<sup>3,4</sup> including the following:
  - ▶ Tumor diameter (clinical, gross, and/or microscopic)
  - ▶ Histologic grade (degree of cellular differentiation)
  - ▶ Depth of invasion: both 1) distance from the granular layer of adjacent normal epidermis to the base of the specimen (in mm), and 2) anatomic level of invasion if beyond subcutaneous fat
  - ▶ Perineural invasion if involving nerve below dermis or if largest nerve involved is >0.1 mm in caliber
- For Mohs excisions, reporting of these elements is also encouraged. As depth of invasion (in mm) may not be reliably ascertained on Mohs specimens, anatomic level of invasion can be reported, which informs T classification for AJCC staging. Submission of a central section of tissue at the area of deepest invasion for permanent section evaluation may be considered to evaluate and document high-risk features, facilitate staging if features were questionable or ambiguous on Mohs sections, and obtain ancillary molecular studies, as indicated.

<sup>1</sup> High-risk histologic subtypes include acantholytic, adenosquamous, desmoplastic, or carcinosarcomatous; low-risk histologic subtypes include verrucous and keratoacanthomatous SCC.

<sup>2</sup> Alam M, Armstrong A, Baum C, et al. Guidelines of care for the management of cutaneous squamous cell carcinoma. J Am Acad Dermatol 2018;78:560-578.

<sup>3</sup> Califano JA, Lydiatt WM, Nehal KS, et al. Cutaneous squamous cell carcinoma of the head and neck. In: Amin MB, Edge S, Greene F, et al., eds. AJCC Cancer Staging Manual (ed Eighth). New York: Springer International Publishing; 2017:171-181.

<sup>4</sup> Karia PS, Jambusaria-Pahlajani A, Harrington DP, et al. Evaluation of American Joint Committee on Cancer, International Union Against Cancer, and Brigham and Women's Hospital tumor staging for cutaneous squamous cell carcinoma. J Clin Oncol 2014;32:327-334.

**Note:** For more information regarding the categories and definitions used for the NCCN Evidence Blocks™, see page [EB-1](#).

All recommendations are category 2A unless otherwise indicated.

Clinical Trials: NCCN believes that the best management of any patient with cancer is in a clinical trial. Participation in clinical trials is especially encouraged.



# NCCN Guidelines Version 1.2020

## Squamous Cell Skin Cancer

### NCCN Evidence Blocks™

[NCCN Guidelines Index](#)  
[Table of Contents](#)  
[Discussion](#)

#### RISK FACTORS FOR LOCAL RECURRENCE OR METASTASES

	<u>Low Risk</u>	<u>High Risk</u>
<b>H&amp;P</b> <b>Location/size<sup>1</sup></b>  <b>Borders</b> <b>Primary vs. recurrent</b> <b>Immunosuppression</b> <b>Site of prior RT or chronic inflammatory process</b> <b>Rapidly growing tumor</b> <b>Neurologic symptoms</b>	<b>Area L &lt;20 mm</b> <b>Area M &lt;10 mm<sup>4</sup></b>  <b>Well-defined</b> <b>Primary</b> (-) (-) (-) (-)	<b>Area L ≥20 mm</b> <b>Area M ≥10 mm</b> <b>Area H<sup>5</sup></b> <b>Poorly defined</b> <b>Recurrent</b> (+) (+) (+) (+)
<b>Pathology (See SCC-A)</b> <b>Degree of differentiation</b> <b>Acantholytic (adenoid), adenosquamous (showing mucin production), desmoplastic, or metaplastic (carcinosarcomatous) subtypes</b> <b>Depth<sup>2,3</sup>: Thickness or level of invasion</b> <b>Perineural, lymphatic, or vascular involvement</b>	<b>Well or moderately differentiated</b> (-)  <b>≤6 mm and no invasion beyond subcutaneous fat</b> (-)	<b>Poorly differentiated</b> (+)  <b>&gt;6 mm or invasion beyond subcutaneous fat</b> (+)

Area H = “mask areas” of face (central face, eyelids, eyebrows, periorbital, nose, lips [cutaneous and vermilion], chin, mandible, preauricular and postauricular skin/sulci, temple, and ear), genitalia, hands, and feet  
 Area M = cheeks, forehead, scalp, neck, and pretibia  
 Area L = trunk and extremities (excluding hands, nail units, pretibia, ankles, and feet)

<sup>1</sup> Must include peripheral rim of erythema.

<sup>2</sup> If clinical evaluation of incisional biopsy suggests that microstaging is inadequate, consider narrow margin excisional biopsy.

<sup>3</sup> Deep invasion is defined as invasion beyond the subcutaneous fat OR >6 mm (as measured from the granular layer of adjacent normal epidermis to the base of the tumor, consistent with AJCC 8th edition).

<sup>4</sup> Location independent of size may constitute high risk.

<sup>5</sup> Area H constitutes high risk based on location, independent of size. Narrow excision margins due to anatomic and functional constraints are associated with increased recurrence rates with standard histologic processing. Complete margin assessment such as with Mohs micrographic surgery is recommended for optimal tumor clearance and maximal tissue conservation. For tumors <6 mm in size, without other high-risk features, other treatment modalities may be considered if at least 4-mm clinically tumor-free margins can be obtained without significant anatomic or functional distortions.

**Note: For more information regarding the categories and definitions used for the NCCN Evidence Blocks™, see page EB-1.**

**All recommendations are category 2A unless otherwise indicated.**

**Clinical Trials: NCCN believes that the best management of any patient with cancer is in a clinical trial. Participation in clinical trials is especially encouraged.**



## IDENTIFICATION AND MANAGEMENT OF HIGH-RISK PATIENTS

### Definition

- **Certain patient groups are at high risk for developing multiple squamous cell skin cancers and tumors that can behave aggressively. These include:**
  - ▶ Organ transplant recipients
  - ▶ Other settings of immunosuppression (eg, lymphoma, chronic lymphocytic leukemia, drug-induced, HIV)
  - ▶ Xeroderma pigmentosum
- **Within these high-risk groups, individual high-risk patients should be identified for closer follow-up.**
- **Important individual risk factors include:**
  - ▶ Total number of tumors
  - ▶ Frequency of development
  - ▶ Occurrence of aggressive tumors (eg, extension beyond cutaneous structures, perineural involvement, large and poorly differentiated, having ≥3 risk factors for recurrence) ([See Risk Factors for Local Recurrence or Metastases \[SCC-B\]](#))

### Diagnosis

- **Skin lesions in these high-risk populations may be difficult to assess clinically. Therefore, a low threshold for performing skin biopsies of suspect lesions is necessary.**
- **In these patients, urgent diagnosis and treatment of lesions are important, and nodal staging (CT with contrast and/or ultrasound or pathologic evaluation) may be considered in those with significant risk of nodal metastases.**

**Note:** For more information regarding the categories and definitions used for the NCCN Evidence Blocks™, see page [EB-1](#).

All recommendations are category 2A unless otherwise indicated.

Clinical Trials: NCCN believes that the best management of any patient with cancer is in a clinical trial. Participation in clinical trials is especially encouraged.

**IDENTIFICATION AND MANAGEMENT OF HIGH-RISK PATIENTS****Treatment of Precancers (Diffuse Actinic Keratoses, Field Cancerization)**

- Actinic keratoses should be treated at first development.
  - ▶ Accepted treatment modalities include cryotherapy, topical 5-fluorouracil (5-FU) with or without calcipotriol (calcipotriene), topical imiquimod, topical ingenol mebutate, photodynamic therapy (eg, aminolevulinic acid [ALA], porfimer sodium), and C&E. For hyperkeratotic actinic keratoses, pretreatment with topical tazarotene, curettage, or topical keratolytics (topical urea, lactic acid, and salicylic acid) prior to above therapies may be considered.
  - ▶ Other modalities that may be considered include topical diclofenac (category 2B), chemical peel (trichloroacetic acid), and ablative skin resurfacing (eg, laser, dermabrasion).
- Actinic keratoses that have an atypical clinical appearance or do not respond to appropriate therapy should be biopsied for histologic evaluation.
- Ablative laser vermilionectomy may be of value in the treatment of extensive actinic cheilitis.

**Treatment of Skin Cancers**

- Because patients in high-risk groups may develop multiple lesions in short periods of time, destructive therapy (eg, C&E, cryotherapy) may be a preferred treatment for clinically low-risk tumors, because of the ability to treat multiple lesions at a single patient visit. If C&E has been performed based solely on the clinical appearance of a low-risk tumor, the pathology from the biopsy taken at the time of C&E should be reviewed to make sure there are no high-risk pathologic features that would suggest the need for further therapy beyond C&E.
- In patients who develop multiple adjacent tumors in close proximity, surgical excision of invasive disease sometimes does not include surrounding in situ disease, and tissue rearrangement should be minimized. In situ disease may then be treated with secondary approaches.
- Compared to the low-risk population, RT is used more frequently as an adjuvant therapy in high-risk patients and for perineural disease.
- Satellite lesions and in-transit cutaneous metastases may occur more frequently in this population. They must be treated aggressively with multidisciplinary consultation.
- In organ transplant recipients and other patients undergoing immunosuppressive therapy, decreasing the level of immunosuppressive therapy and/or incorporating mTOR inhibitors may be considered in cases of life-threatening skin cancer or the rapid development of multiple tumors.

**Follow-Up**

- Follow-up schedules should be titrated to the frequency of tumor development, and in rare cases may be as frequently as weekly.

[See Evidence blocks on SCC-C \(EB-1\)](#)

**Note:** For more information regarding the categories and definitions used for the NCCN Evidence Blocks™, see page [EB-1](#).

All recommendations are category 2A unless otherwise indicated.

Clinical Trials: NCCN believes that the best management of any patient with cancer is in a clinical trial. Participation in clinical trials is especially encouraged.



## IDENTIFICATION AND MANAGEMENT OF HIGH-RISK PATIENTS

### Patient Education

- Individual risk assessment is necessary and should be discussed.
- Both extensive and repetitive patient education regarding sun avoidance and protection is required.
- Sun avoidance and protection methods must be stringent.
- Monthly self examination of all skin surfaces is recommended. With a history of invasive skin cancer, self examination of the lymph nodes should be taught and performed.
- Rapid entrance into the health care delivery system at the onset of tumor development is critical.
- Patient education should begin, in the case of organ transplant recipients, at transplantation and in the case of xeroderma pigmentosum, at birth or diagnosis.

### Prevention

- Use of oral retinoids (acitretin, isotretinoin) has been effective in reducing the development of actinic keratoses and SCC in some high-risk patients. Side effects of oral retinoids may be significant. Therapeutic effects disappear shortly after cessation of the drug. Oral retinoids are teratogenic and must be used with extreme caution in women of child-bearing potential. Topical retinoids have been shown not to reduce development of actinic keratosis or SCC.
- Use of nicotinamide may be effective in reducing the development of SCCs.
- Aggressive treatment of precancers can prevent the development of subsequent invasive tumors.

[See Evidence blocks on SCC-C \(EB-1\)](#)

**Note:** For more information regarding the categories and definitions used for the NCCN Evidence Blocks™, see page [EB-1](#).

All recommendations are category 2A unless otherwise indicated.

Clinical Trials: NCCN believes that the best management of any patient with cancer is in a clinical trial. Participation in clinical trials is especially encouraged.

**TREATMENT OF PRECANCERS: THERAPY FOR ACTINIC KERATOSES (See SCC-C 2 of 3)**

Topical 5-fluorouracil	
Topical 5-fluorouracil/calcipotriol (calcipotriene)	
Topical imiquimod	
Photodynamic therapy with ALA	
Photodynamic therapy with porfimer sodium	
Topical diclofenac	
Chemical peel with trichloroacetic acid	
Topical Ingenol Mebutate	
<b>Pretreatment for hyperkeratotic actinic keratoses*</b>	
Topical tazarotene	
Topical keratolytics (topical urea, lactic acid, and salicylic acid)	

**PREVENTION: THERAPY TO PREVENT DEVELOPMENT OF ACTINIC KERATOSES AND SCC (See SCC-C 3 of 3)**

Acitretin	
Isotretinoin	
Nicotinamide	

\*Pretreatment administered prior to one of the following treatment options: cryotherapy, topical 5-fluorouracil with or without calcipotriol (calcipotriene), topical imiquimod, topical ingenol mebutate, photodynamic therapy (eg, aminolevulinic acid [ALA], porfimer sodium), or C&E.

**Note: For more information regarding the categories and definitions used for the NCCN Evidence Blocks™, see page EB-1.**  
**All recommendations are category 2A unless otherwise indicated.**  
**Clinical Trials: NCCN believes that the best management of any patient with cancer is in a clinical trial. Participation in clinical trials is especially encouraged.**



## PRINCIPLES OF TREATMENT FOR SQUAMOUS CELL SKIN CANCER

- **The primary goals of treatment of SCCs are the complete removal of the tumor and the maximal preservation of function and cosmesis. All treatment decisions should be customized to account for the particular factors present in the individual case and for the patient's preference.**
- **Surgical approaches often offer the most effective and efficient means for accomplishing cure, but considerations of function, cosmesis, and patient preference may lead to choosing RT as primary treatment in order to achieve optimal overall results.**
- **In certain patients at high risk for multiple primary tumors, increased surveillance and consideration of prophylactic measures may be indicated. ([See Identification and Management of High-Risk Patients \[SCC-C\]](#))**
- **In patients with SCC in situ (Bowen's disease), alternative therapies such as topical 5-FU, topical imiquimod, photodynamic therapy (eg, ALA, porfimer sodium), or vigorous cryotherapy may be considered even though cure rates may be lower than with surgical treatment modalities.**
- **When Mohs micrographic surgery with margin assessment is being performed and the preoperative biopsy is considered insufficient for providing all the staging information required to properly treat the tumor, submission of the central specimen for vertical paraffin-embedded permanent sections or documentation of staging parameters in Mohs report is recommended.**
- **Use of nicotinamide may be effective in reducing the development of SCCs.**

[See Evidence blocks on SCC-D \(EB-1\)](#)

**Note: For more information regarding the categories and definitions used for the NCCN Evidence Blocks™, see page [EB-1](#).**

**All recommendations are category 2A unless otherwise indicated.**

**Clinical Trials: NCCN believes that the best management of any patient with cancer is in a clinical trial. Participation in clinical trials is especially encouraged.**



# NCCN Guidelines Version 1.2020

## Squamous Cell Skin Cancer

### NCCN Evidence Blocks™

5					
4					
3					
2					
1					
	E	S	Q	C	A

E = Efficacy of Regimen/Agent  
S = Safety of Regimen/Agent  
Q = Quality of Evidence  
C = Consistency of Evidence  
A = Affordability of Regimen/Agent

[NCCN Guidelines Index](#)  
[Table of Contents](#)  
[Discussion](#)

#### EVIDENCE BLOCKS FOR ALTERNATIVE THERAPY FOR SCC IN SITU (BOWEN'S DISEASE) ([See SCC-D](#))

Topical 5-fluorouracil	
Topical imiquimod	
Photodynamic therapy with ALA	
Photodynamic therapy with porfimer sodium	

**Note:** For more information regarding the categories and definitions used for the NCCN Evidence Blocks™, see page [EB-1](#).

All recommendations are category 2A unless otherwise indicated.

Clinical Trials: NCCN believes that the best management of any patient with cancer is in a clinical trial. Participation in clinical trials is especially encouraged.

#### PRINCIPLES OF RADIATION THERAPY FOR SQUAMOUS CELL SKIN CANCER

##### General Principles

- Protracted fractionation is associated with improved cosmetic results and should be utilized for poorly vascularized or cartilaginous areas.
- For extensive perineural invasion, clinically evident perineural involvement, or involvement of named nerves (particularly in the head and neck region), consider including the course of the local nerves proximally.
- RT is contraindicated in genetic conditions predisposing to skin cancer (eg, basal cell nevus syndrome) and relatively contraindicated for patients with connective tissue diseases (eg, scleroderma).
- Given higher complication rates, re-irradiation should not be routinely utilized for recurrent disease within a prior radiation field.
- There are insufficient long-term efficacy and safety data to support the routine use of electronic surface brachytherapy.
- Radioisotope brachytherapy could be considered in highly selected cases.

##### General Treatment Information

<u>Primary Tumor</u>	<u>Examples of Dose Fractionation and Treatment Duration</u>
<u>Definitive RT</u> Tumor diameter <2 cm	60–64 Gy over 6 to 7 weeks 50–55 Gy over 3 to 4 weeks 40 Gy over 2 weeks 30 Gy in 5 fractions over 2 to 3 weeks
Tumor diameter ≥2 cm, T3/T4, or those with invasion of bone or deep tissue	60–70 Gy over 6 to 7 weeks 45–55 Gy over 3 to 4 weeks
<u>Postoperative Adjuvant RT</u>	60–64 Gy over 6 to 7 weeks 50 Gy over 4 weeks
<u>Regional Disease</u>	
• Lymph node regions, after lymph node dissection	
▶ Negative margins, no ECE	50–60 Gy over 5 to 6 weeks
▶ Positive margins or ECE	60–66 Gy over 6 to 7 weeks
• Lymph node regions, without lymph node dissection	
▶ Clinically negative, at risk	50 Gy over 5 weeks
▶ Clinically positive	60–70 Gy over 6 to 7 weeks
• Clinically at-risk nerves	50–60 Gy over 5 to 6 weeks

**Note:** For more information regarding the categories and definitions used for the NCCN Evidence Blocks™, see page [EB-1](#).

All recommendations are category 2A unless otherwise indicated.

Clinical Trials: NCCN believes that the best management of any patient with cancer is in a clinical trial. Participation in clinical trials is especially encouraged.

**PRINCIPLES OF SYSTEMIC THERAPY FOR SQUAMOUS CELL SKIN CANCER****Local Disease Amenable to Surgery**

- Systemic therapy is not recommended.

**Locally Advanced Disease in Non-Surgical Candidates**

- For potential use with RT: ([See SCC-3](#))
  - Options for multidisciplinary team to consider for use in combination with RT for patients who have residual disease and further surgery is not feasible:
    - ◊ Clinical trial<sup>1,2</sup>
    - ◊ Chemotherapy
- Systemic therapy alone: ([See SCC-3](#))
  - Options for multidisciplinary team to consider for complicated cases of locally advanced disease in which curative surgery and curative RT are not feasible:
    - ◊ Cemiplimab-rwlc<sup>1,2</sup> (preferred)
    - ◊ Clinical trial<sup>1,2</sup>

**Regional Disease (See SCC-4)**

- For most cases of fully resected regional disease, adjuvant systemic therapy is not recommended, unless within a clinical trial. ([See SCC-4](#) and [SCC-5](#))
- For patients with completely resected ECE or similar high-risk regional disease, consider RT ± systemic therapy in the context of a clinical trial.
- Options for patients with inoperable or incompletely resected regional disease:
  - For potential use with RT: ([See SCC-4](#) and [SCC-5](#))
    - ◊ Cisplatin<sup>3</sup> (category 3)
    - ◊ Cisplatin + 5-FU<sup>3</sup> (category 2B)
    - ◊ EGFR inhibitors (eg, cetuximab)<sup>3</sup>
    - ◊ Carboplatin<sup>3</sup> (category 3)
  - Systemic therapy alone, if curative RT not feasible: ([See SCC-4](#))
    - ◊ Cemiplimab-rwlc<sup>1,2</sup> (preferred)
    - ◊ Clinical trial<sup>1,2</sup>
    - ◊ If ineligible for immune checkpoint inhibitors and clinical trials, consider:
      - Cisplatin<sup>3</sup> (category 2B)
      - Cisplatin + 5-FU<sup>3</sup>
      - EGFR inhibitors (eg, cetuximab)<sup>3</sup>
      - Carboplatin<sup>3</sup> (category 2B)

**Regional Recurrence or Distant Metastatic Disease (See SCC-6)**

- Cemiplimab-rwlc<sup>1,2</sup> (preferred) if curative surgery and curative RT are not feasible
- Clinical trial<sup>1,2</sup>
- If ineligible for immune checkpoint inhibitors and clinical trials, consider:
  - Cisplatin ± 5-FU<sup>3</sup>
  - EGFR inhibitors (eg, cetuximab)<sup>3</sup>
  - Carboplatin<sup>3</sup> (category 2B)

**[See Evidence blocks on SCC-F \(EB-1\)](#)**

<sup>1</sup> Recently published phase I–II trial data have shown high response rates (approximately 50%) to cemiplimab-rwlc in patients with locally advanced or metastatic cutaneous squamous cell carcinoma. Preliminary data and the clinical experience of NCCN Panel members suggest that other anti–PD-1 inhibitors may also be effective in this setting.

<sup>2</sup> In solid organ transplant recipients, potential benefit from immune checkpoint inhibitor therapy has to be weighed against a significant risk of organ rejection. For patients receiving immunosuppressive therapy, in consultation with their treating physician, consider dose reduction of the immunosuppressive agent(s) and/or minimizing the doses of calcineurin inhibitors and/or antimetabolites in favor of mTOR inhibitors where appropriate. Patients with underlying immunodeficiencies, including CLL, were excluded from the phase I–II cemiplimab-rwlc trial, so the efficacy of cemiplimab-rwlc in this population is unclear.

<sup>3</sup> These options have occasionally produced useful responses, but data supporting efficacy are limited.

**Note:** For more information regarding the categories and definitions used for the NCCN Evidence Blocks™, see page [EB-1](#).

All recommendations are category 2A unless otherwise indicated.

Clinical Trials: NCCN believes that the best management of any patient with cancer is in a clinical trial. Participation in clinical trials is especially encouraged.



# NCCN Guidelines Version 1.2020

## Squamous Cell Skin Cancer

### NCCN Evidence Blocks™

5					E = Efficacy of Regimen/Agent
4					S = Safety of Regimen/Agent
3					Q = Quality of Evidence
2					C = Consistency of Evidence
1					A = Affordability of Regimen/Agent
	E	S	Q	C	A

## SYSTEMIC THERAPY FOR SQUAMOUS CELL SKIN CANCER (See SCC-F)

### Locally Advanced Disease in Non-Surgical Candidates

<b>Systemic therapy alone, to consider for complicated cases of locally advanced disease in which curative surgery and curative RT are not feasible:</b>	
Cemiplimab-rwlc (preferred)	*

### Regional Disease

Options for patients with inoperable or incompletely resected regional disease:

<b>For potential use with RT:</b>	
• Cisplatin (category 3)	*
• Cisplatin + 5-FU (category 2B)	*
• Cetuximab	*
• Carboplatin (category 3)	*
<b>Systemic therapy alone, if curative RT not feasible:</b>	
• Cemiplimab-rwlc (preferred)	*
<b>• To consider if ineligible for immune checkpoint inhibitors and clinical trials:</b>	
▶ Cisplatin (category 2B)	*
▶ Cisplatin + 5-FU	*
▶ Cetuximab	*
▶ Carboplatin (category 2B)	*

### Regional Recurrence or Distant Metastatic Disease

<b>If curative surgery and Curative RT are not feasible:</b>	
• Cemiplimab-rwlc (preferred)	*
<b>To consider if ineligible for immune checkpoint inhibitors and clinical trials:</b>	
• Cisplatin	*
• Cisplatin + 5-FU	*
• Cetuximab	*
• Carboplatin (category 2B)	*

\*Evidence Block development in progress.

**Note: For more information regarding the categories and definitions used for the NCCN Evidence Blocks™, see page EB-1.**  
All recommendations are category 2A unless otherwise indicated.  
Clinical Trials: NCCN believes that the best management of any patient with cancer is in a clinical trial. Participation in clinical trials is especially encouraged.

**American Joint Committee on Cancer (AJCC)****TNM Staging Classification for Cutaneous Carcinoma of the Head and Neck (8th ed., 2017)<sup>1</sup>****Table 1. Definitions for T, N, M**

<b>T</b>	<b>Primary Tumor</b>
<b>TX</b>	Primary tumor cannot be assessed
<b>Tis</b>	Carcinoma <i>in situ</i>
<b>T1</b>	Tumor smaller than or equal to 2 cm in greatest dimension
<b>T2</b>	Tumor larger than 2 cm, but smaller than or equal to 4 cm in greatest dimension
<b>T3</b>	Tumor larger than 4 cm in maximum dimension or minor bone erosion or perineural invasion or deep invasion*
<b>T4</b>	Tumor with gross cortical bone/marrow, skull base invasion and/or skull base foramen invasion
<b>T4a</b>	Tumor with gross cortical bone/marrow invasion
<b>T4b</b>	Tumor with skull base invasion and/or skull base foramen involvement

\*Deep invasion is defined as invasion beyond the subcutaneous fat or >6 mm (as measured from the granular layer of adjacent normal epidermis to the base of the tumor); perineural invasion for T3 classification is defined as tumor cells within the nerve sheath of a nerve lying deeper than the dermis or measuring 0.1 mm or larger in caliber, or presenting with clinical or radiographic involvement of named nerves without skull base invasion or transgression.

**Clinical N (cN)**

<b>cN</b>	<b>Regional Lymph Nodes</b>
<b>NX</b>	Regional lymph nodes cannot be assessed
<b>N0</b>	No regional lymph node metastasis
<b>N1</b>	Metastasis in a single ipsilateral lymph node, 3 cm or smaller in greatest dimension and ENE(-)
<b>N2</b>	Metastasis in a single ipsilateral node larger than 3 cm but not larger than 6 cm in greatest dimension and ENE(-); or metastases in multiple ipsilateral lymph nodes, none larger than 6 cm in greatest dimension and ENE(-); or in bilateral or contralateral lymph nodes, none larger than 6 cm in greatest dimension and ENE(-)
<b>N2a</b>	Metastasis in a single ipsilateral node larger than 3 cm but not larger than 6 cm in greatest dimension and ENE(-)
<b>N2b</b>	Metastases in multiple ipsilateral nodes, none larger than 6 cm in greatest dimension and ENE(-)
<b>N2c</b>	Metastases in bilateral or contralateral lymph nodes, none larger than 6 cm in greatest dimension and ENE(-)
<b>N3</b>	Metastasis in a lymph node larger than 6 cm in greatest dimension and ENE(-); or metastasis in any node(s) and clinically overt ENE [ENE(+)]
<b>N3a</b>	Metastasis in a lymph node larger than 6 cm in greatest dimension and ENE(-)
<b>N3b</b>	Metastasis in any node(s) and ENE (+)

Note: A designation of “U” or “L” may be used for any N category to indicate metastasis above the lower border of the cricoid (U) or below the lower border of the cricoid (L). Similarly, clinical and pathological extranodal extension (ENE) should be recorded as ENE(-) or ENE(+).

<sup>1</sup> These staging tables are for cutaneous squamous cell carcinoma, cutaneous carcinoma of the head and neck, and all other nonmelanoma skin carcinomas of the head and neck (except Merkel cell carcinoma). Anatomic site of external vermilion lip is included because it has a more similar embryologic origin to skin, and its etiology—which is often based on ultraviolet exposure—is more similar to other nonmelanoma skin cancers. The AJCC Staging Manual, Eighth Edition does not include staging for cutaneous carcinoma outside the head and neck.

Used with the permission of the American College of Surgeons, Chicago, Illinois. The original source for this information is the AJCC Cancer Staging Manual, Eighth Edition (2017) published by Springer International Publishing.

**Continued**



**American Joint Committee on Cancer (AJCC)**  
**TNM Staging Classification for Cutaneous Carcinoma of the Head and Neck (8th ed., 2017)<sup>1</sup>**

**Pathological N (pN)**

**pN Regional Lymph Nodes**

**NX** Regional lymph nodes cannot be assessed

**N0** No regional lymph node metastasis

**N1** Metastasis in a single ipsilateral lymph node, 3 cm or smaller in greatest dimension and ENE(-)

**N2** Metastasis in a single ipsilateral lymph node, 3 cm or smaller in greatest dimension and ENE(+);  
or larger than 3 cm but not larger than 6 cm in greatest dimension and ENE(-);  
or metastases in multiple ipsilateral lymph nodes, none larger than 6 cm in greatest dimension and ENE(-);  
or in bilateral or contralateral lymph node(s), none larger than 6 cm in greatest dimension, ENE(-)

**N2a** Metastasis in single ipsilateral node 3 cm or smaller in greatest dimension and ENE(+);  
or a single ipsilateral node larger than 3 cm but not larger than 6 cm in greatest dimension and ENE(-)

**N2b** Metastases in multiple ipsilateral nodes, none larger than 6 cm in greatest dimension and ENE(-)

**N2c** Metastases in bilateral or contralateral lymph node(s), none larger than 6 cm in greatest dimension and ENE(-)

**N3** Metastasis in a lymph node larger than 6 cm in greatest dimension and ENE(-);  
or in a single ipsilateral node larger than 3 cm in greatest dimension and ENE(+);  
or multiple ipsilateral, contralateral, or bilateral nodes, any with ENE(+);  
or a single contralateral node of any size and ENE(+)

**N3a** Metastasis in a lymph node larger than 6 cm in greatest dimension and ENE(-)

**N3b** Metastasis in a single ipsilateral node larger than 3 cm in greatest dimension and ENE(+);  
or multiple ipsilateral, contralateral, or bilateral nodes, any with ENE(+);  
or a single contralateral node of any size and ENE(+)

Note: A designation of “U” or “L” may be used for any N category to indicate metastasis above the lower border of the cricoid (U) or below the lower border of the cricoid (L). Similarly, clinical and pathological extranodal extension (ENE) should be recorded as ENE(-) or ENE(+).

<sup>1</sup> These staging tables are for cutaneous squamous cell carcinoma, cutaneous carcinoma, basal cell carcinoma of the head and neck, and all other nonmelanoma skin carcinomas of the head and neck (except Merkel cell carcinoma).

Anatomic site of external vermilion lip is included because it has a more similar embryologic origin to skin, and its etiology—which is often based on ultraviolet exposure—is more similar to other nonmelanoma skin cancers. The AJCC Staging Manual, Eighth Edition does not include staging for cutaneous carcinoma outside the head and neck. Used with the permission of the American College of Surgeons, Chicago, Illinois. The original source for this information is the AJCC Cancer Staging Manual, Eighth Edition (2017) published by Springer International Publishing.

**M Distant Metastasis**

**M0** No distant metastasis

**M1** Distant metastasis

**G Histologic Grade**

**GX** Grade cannot be assessed

**G1** Well differentiated

**G2** Moderately differentiated

**G3** Poorly differentiated

**G4** Undifferentiated

**Table 2. AJCC Prognostic Stage Groups**

	<b>T</b>	<b>N</b>	<b>M</b>
<b>Stage 0</b>	Tis	N0	M0
<b>Stage I</b>	T1	N0	M0
<b>Stage II</b>	T2	N0	M0
<b>Stage III</b>	T3	N0	M0
	T1	N1	M0
	T2	N1	M0
	T3	N1	M0
<b>Stage IV</b>	T1	N2	M0
	T2	N2	M0
	T3	N2	M0
	Any T	N3	M0
	T4	Any N	M0
	Any T	Any N	M1



#### NCCN Categories of Evidence and Consensus

<b>Category 1</b>	Based upon high-level evidence, there is uniform NCCN consensus that the intervention is appropriate.
<b>Category 2A</b>	Based upon lower-level evidence, there is uniform NCCN consensus that the intervention is appropriate.
<b>Category 2B</b>	Based upon lower-level evidence, there is NCCN consensus that the intervention is appropriate.
<b>Category 3</b>	Based upon any level of evidence, there is major NCCN disagreement that the intervention is appropriate.

All recommendations are category 2A unless otherwise indicated.

**Discussion**

This discussion is being updated to correspond with the newly updated algorithm. Last updated 10/05/17

**Table of Contents**

Overview .....	MS-2	NCCN Recommendations.....	MS-25
Clinical Presentation and Workup .....	MS-3	Follow-Up .....	MS-25
Risk Stratification .....	MS-3	NCCN Recommendations.....	MS-25
Risk Factors for SCC Local Recurrence or Metastasis.....	MS-3	References.....	MS-27
Pathologic Risk Factors for SCC .....	MS-5		
Patients at High Risk of Developing Multiple SCCs.....	MS-7		
Local Treatment for SCC .....	MS-7		
Curettage and Electrodesiccation .....	MS-7		
Excision with Postoperative Margin Assessment .....	MS-8		
Mohs Micrographic Surgery or Excision with Complete Circumferential Peripheral and Deep Margin Assessment (CCPDMA) .....	MS-9		
Sentinel Lymph Node Biopsy.....	MS-10		
Radiation Therapy.....	MS-10		
Superficial Therapies .....	MS-12		
Systemic Therapy for Local High-Risk SCC.....	MS-13		
NCCN Recommendations for Treating Local SCC .....	MS-14		
Management of Patients at High Risk of Developing Multiple SCCs..	MS-15		
Treatment of Precancers in High-risk Patients .....	MS-15		
Treatment of SCC in High-Risk Patients .....	MS-16		
Prevention in High-Risk Patients .....	MS-16		
Patient Education for High-Risk Patients .....	MS-18		
Regional Lymph Node Involvement in SCC.....	MS-19		
NCCN Recommendations for Workup for Suspicion of Regional Lymph Node Involvement.....	MS-19		
Treatment of SCC with Regional Lymph Node Involvement .....	MS-20		
Systemic Therapy for Regional Disease .....	MS-23		
NCCN Recommendations for Treatment of Regional Disease.....	MS-23		
Recurrence and Metastasis .....	MS-24		
Systemic Therapy for Distant Metastatic Disease .....	MS-24		



## Overview

Basal cell and squamous cell skin cancers, collectively known as non-melanoma skin cancers (NMSCs) or keratinocyte carcinomas, are more prevalent than all other cancers combined.<sup>1</sup> It is estimated that over 5 million keratinocyte carcinoma cases were treated in the United States in 2012, with roughly half of those cases being cutaneous squamous cell carcinomas (cSCCs).<sup>2</sup> Squamous cell carcinoma (SCC) is the second most common skin cancer.<sup>3-9</sup> Numerous population-based studies have demonstrated that the incidence of cSCC is rising rapidly.<sup>2,3,10-16</sup> Some studies show that cSCC incidence rates are rising more rapidly than basal cell carcinoma (BCC), reducing the difference in incidence between these two skin cancers.<sup>4,5,8,9,13</sup> Although rarely metastatic, cSCC can produce substantial local destruction along with disfigurement and may involve extensive areas of soft tissue, cartilage, and bone. cSCCs generally have a good prognosis, with 5-year survival  $\geq 90\%$ .<sup>3,17,18</sup>

A number of risk factors are associated with development of cSCC. The most recognized environmental carcinogen is sunlight. Evidence reveals that chronic sun exposure, total site-specific exposure, and number of site-specific sunburns are strongly correlated with development of cSCC.<sup>6,15,19-26</sup> Due to the link with chronic sun exposure, cSCC rates are higher in occupations involving outdoor work.<sup>20,27-30</sup> As a result of cumulative sun exposure, the risk of cSCC increases with age, particularly in sun-exposed sites.<sup>4,12-15,25</sup>

Indoor tanning is also significantly associated with cSCC. According to a large meta-analysis, including 80,661 participants, any exposure to indoor tanning increases the risk of cSCC by 67%.<sup>31</sup> A meta-analysis based on a total of 406,696 individuals showed that the prevalence of indoor tanning is much higher than previously thought, with 35% of adults in the United States having some exposure to indoor tanning (95% CI, 27%–44%), and 13% using indoor tanning in the past year (95% CI, 11%–16%).

Prevalence of indoor tanning was even higher among university students, with 59% having some exposure (95% CI, 42%–77%), and 43% (95% CI, 22%–65%) having used indoor tanning in the past year.<sup>32</sup>

Individuals with fair skin, hair, and eye color who have received too much sun exposure are at the greatest risk for cSCC due to susceptibility to oncogenic UV damage in genes associated with pigmentation.<sup>19-21,23,26,33,34</sup> Most of these tumors develop on sun-exposed skin sites, especially the head and neck area.<sup>9,12,14,15,35</sup>

cSCCs are also known to develop in association with scars or chronic wounds (Marjolin's ulcer).<sup>36-39</sup> SCC is the most common type of malignancy developing in chronic scars or chronic ulcers.<sup>36,40-47</sup> SCC lesions arising in scars or chronic wounds tend to have poor prognosis and are difficult to treat (ie, have higher risk of recurrence after treatment).<sup>48-54</sup>

Actinic keratoses are sun-induced precancerous lesions, while Bowen's disease refers to cSCC in situ. Both lesions, if left untreated, can progress to invasive cSCC with the potential for metastasis.<sup>29,55-64</sup>

Certain genetic syndromes greatly predispose affected individuals to cSCC formation, such as albinism (in which skin pigment is absent)<sup>44,65-72</sup> and xeroderma pigmentosum (in which defects exist in UV light-induced unscheduled DNA repair).<sup>73-79</sup>

Certain settings of immunosuppression (most notably organ transplantation, lymphoma, chronic lymphocytic leukemia, drug-induced immunosuppression, and HIV) also predispose affected individuals to cSCC.<sup>80-96</sup> Analyses of transplant registries have reported a 5-fold to 113-fold increase in incidence of cSCC in transplant recipients compared to the general population.<sup>82,83,93,97</sup>



## Clinical Presentation and Workup

On clinical presentation of the patient with a suspicious lesion, workup for cSCC begins with a history and physical examination, with an emphasis on a complete skin and regional lymph node examination. A full skin examination is recommended because individuals with a skin cancer often have additional, concurrent precancers or cancers located at other, usually sun-exposed skin sites. These individuals are also at increased risk of developing cutaneous melanoma.<sup>12,16,29,98-107</sup> A skin biopsy is then performed on any suspicious lesion. The biopsy should include deep reticular dermis if the lesion is suspected to be more than a superficial process. This procedure is preferred because an infiltrative histology may sometimes be present only at the deeper, advancing margins of a tumor and superficial biopsies will frequently miss this component.<sup>108,109</sup> Skin lesions in high-risk populations may be difficult to assess clinically; therefore, a low threshold for performing skin biopsies in these patients is necessary. The workup for cSCC is also recommended for cSCC in situ showing full-thickness epidermal atypia, excluding actinic keratoses. Although basosquamous carcinoma may behave as aggressively as cSCC, it is a subtype of BCC and should be treated as such.<sup>110-113</sup>

Imaging studies of the area of interest should be done when extensive disease is suspected, such as bone or deep soft tissue involvement, and perineural, lymphatic, or vascular invasion, as it may alter treatment selection.<sup>114,115</sup> Because of its higher sensitivity, MRI with contrast is preferred over CT with contrast if perineural disease or deep soft tissue involvement is suspected.<sup>116-118</sup> Although rare, skin cancers may present with the appearance of deep extension, for example, into bone or the orbit. In such cases, preoperative imaging studies may be useful to help assess the extent of soft tissue or bony involvement. If bone disease is expected, CT with contrast is preferred unless contraindicated.

The presence of a palpable regional lymph node or abnormal lymph nodes identified by imaging studies should prompt a fine-needle aspiration (FNA) or core biopsy of suspicious node(s) and further workup for clinical staging and preoperative assessment (see *Regional Lymph Node Involvement in SCC*).

## Risk Stratification

After workup, a risk assessment of the primary tumor should be performed to determine the treatment plan and follow-up for patients. For localized disease, the NCCN panel examined risk factors for cSCC associated with recurrence and metastasis. These are listed in table format in the algorithm (See *Risk Factors for Local Recurrence or Metastases* in the algorithm). If any high-risk feature is present, the patient should be managed according to the high-risk treatment pathway for local cSCC.

The AJCC 7<sup>th</sup> edition staging system for cSCC reflects many but not all of the features that the NCCN panel has incorporated to designate local high-risk primary tumors (T2 vs. T1).<sup>119,120</sup> Alternative staging systems have been proposed to more accurately define high-risk groups among patients with clinically localized disease,<sup>17,121,122</sup> and have been independently tested.<sup>107,123-125</sup> These studies and other emerging data<sup>126-128</sup> have led to significant revisions to criteria for determining T-stage in the recently published AJCC 8<sup>th</sup> edition staging system of cSCC.<sup>129</sup>

## Risk Factors for SCC Local Recurrence or Metastasis

### *Location and Size*

Anatomic location has been known to be a risk factor for cSCC recurrence and metastasis for many years.<sup>48,126,130,131</sup> In general, cSCCs that develop in the head and neck area are more likely to recur than those developing on the trunk and extremities. SCCs that develop on the genitalia, mucosal surfaces, and ears are also at greater risk of metastasizing.<sup>17,48,125,131,132</sup> The



concept of a so-called high-risk “mask area of the face” dates back at least to 1983.<sup>133,134</sup>

For cSCC tumors with diameter less than 2 cm, risk stratification by location and size is largely based on extrapolation from older data in BCC.<sup>135,136</sup> This 27-year retrospective review of 5755 BCCs showed that high-risk sites correspond roughly to the mask areas of the face, and that recurrences after standard excision or curettage and electrodesiccation (C&E) were significantly more common when tumors in high-risk locations were 6 mm or more in diameter and when tumors in moderate-risk locations were 10 mm or more in diameter. Therefore, for the purpose of determining which tumors should be removed with Mohs micrographic surgery (MMS) or excision with complete circumferential peripheral and deep margin assessment (CCPDMA) rather than standard excision or C&E, the NCCN panel has defined the following as high risk: 1) tumors in area L (low-risk region) that are  $\geq 20$  mm; 2) tumors in area M (moderate-risk region) that are  $\geq 10$  mm; and 3) tumors in area H (high-risk region) of any size. Areas L, M, and H are defined in detail in the algorithm under *Risk Factors for Local Recurrence or Metastases*. Similar cutoffs are recommended in the appropriate use criteria (AUC) for MMS from the American Academy of Dermatology (AAD) in collaboration with the American College of Mohs Surgery, American Society for Dermatologic Surgery Association, and American Society for Mohs Surgery.<sup>137</sup>

Size also has been shown to be a risk factor for cSCC metastasis.<sup>48,49,126,138-140</sup> Although various different divisions have been used, the most recent and robust data support that tumors  $> 2$  cm are at higher risk of metastasis and poorer disease-specific survival.<sup>17,48-50,121,122,125,126,141,142</sup>

### **Primary Versus Recurrent Disease**

The higher risk of recurrence and metastasis for recurrent versus primary disease has been extensively documented in the literature.<sup>48,51,141,143,144</sup>

### **Immunosuppression**

In addition to increasing the risk of cSCC development, immunosuppression has been shown to be associated with poorer outcomes in large meta-analyses,<sup>48,125</sup> and prospective<sup>126</sup> and retrospective studies.<sup>121,145-155</sup> Each of these studies showed that immunosuppression was associated with at least one measure of poor outcome (recurrence, metastasis, or death), but results are inconsistent regarding which of these outcomes are effected. These studies cover a broad range of extent of disease and treatment approaches, suggesting that immunosuppression is associated with poor prognosis regardless of treatment approach used or the stage of disease at time of treatment.

A few studies from the organ transplant literature have evaluated other risk factors that might be linked to the higher rates of SCC recurrence and metastasis among transplant patients.<sup>124,154,156,157</sup> A retrospective review of 307 patients with cSCC confirmed that those who received organ transplants had more aggressive disease than those who did not, and that SCCs in transplant patients were more likely to have deep tissue spread and perineural and lymphatic invasion at presentation.<sup>154</sup> Other retrospective studies found diffuse/focal spindle cell morphology, evidence of human papillomavirus (HPV) infection, and aggressive subclinical extension to be more likely in SCCs from transplant versus non-transplant patients.<sup>156,158</sup> Two other large retrospective studies reported high rates of SCC recurrence and metastasis among transplant patients despite the fact that most SCCs were stage I/II at presentation.<sup>124,157</sup> The presence of multiple primaries has been shown to be associated with development of high-grade disease;<sup>107</sup> however, uncertainty remains whether the increased rate of SCC metastasis in transplant patients is simply because of a greater number of tumors per patient or reflects more aggressive tumor behavior at the biological level. Because organ transplant recipients have collectively worse outcomes, these patients and their neoplasms are designated as high risk.

**Site of Prior Radiotherapy or Chronic Inflammatory Process**

Tumors developing in sites of prior radiotherapy refer to primary cSCCs arising in areas previously irradiated for unrelated conditions. (All recurrent tumors, irrespective of prior therapy, are defined as high risk, for reasons described above.) Data from older studies and one more recent study support that prior radiotherapy for unrelated (frequently benign) conditions is a risk factor for NMSC recurrence or metastasis.<sup>52,141,159</sup>

Retrospective studies and meta-analyses have documented increased rates of metastasis for cSCC arising in the setting of chronic scarring or inflammation.<sup>48,49,51,144,160-162</sup>

**Neurologic Symptoms**

In tumors with perineural involvement, clinical symptoms suggesting possible involvement of sensory or motor nerves may occur in up to 40% of cases. Symptoms may include pain, burning, stinging, anesthesia, paresthesia, facial paralysis, diplopia, and blurred vision.<sup>163,164</sup> Any suggestion of neurologic involvement in the region of a cSCC should place that tumor in a high-risk category, as perineural invasion (PNI) is associated with recurrence, metastasis, and poor outcomes.<sup>17,48,121,125,131,138,141,162,165-167</sup> As discussed below, the presence of neurologic symptoms is associated with poorer survival, and recurrence-free survival correlates with the extent of neuronal involvement.<sup>121,168-172</sup>

**Pathologic Risk Factors for SCC****Degree of Differentiation**

In their extensive meta-analysis of risk factors for local recurrence and metastasis of cSCC, Rowe and colleagues found that patients with well-differentiated tumors fared significantly better than those patients with poorly differentiated lesions.<sup>48</sup> Another cohort study of 315 patients also associated differentiation grade with overall survival.<sup>162</sup> Eroglu and colleagues reported differentiation to be a significant risk factor of recurrence in an analysis of 1039 patients.<sup>49</sup> Many other studies, including

some very large retrospective studies (n > 1000) provide supporting evidence that poor differentiation is correlated with cSCC recurrence, metastasis, disease-specific survival, and overall survival.<sup>17,121,122,125,131,140,141,143,144,173-175</sup> Although Broders originally divided cSCC histologically into four groups or grades in 1920, the modern trend has been to reduce the divisions to two groups: 1) well or moderately differentiated; and 2) poorly differentiated.<sup>120,122</sup> The NCCN panel has adopted this modern approach in this guideline.<sup>120,122</sup>

**Histology**

The histologic subtypes of acantholytic (adenoid), adenosquamous (or mucin-producing), and metaplastic (carcinosarcomatous) SCC are rare histologic subtypes.<sup>176</sup> Only case reports and case series document the outcomes of patients with these subtypes, and thus their prognostic significance is debated.<sup>177-184</sup> However, because these tumors may have a high risk of recurrence and likely would not be included in the high-risk category on the basis of their degree of differentiation, the panel decided to list them as separate risk factors.

Another high-risk histologic feature reported in the literature is the presence of desmoplasia. In studies from Germany, desmoplastic cSCC was shown to pose a greatly increased risk of both recurrence and metastasis.<sup>126,185</sup> A retrospective study using the PALGA national registry of the Netherlands reported significantly higher rates of metastasis for desmoplastic versus non-desmoplastic cSCCs: 89% versus 21% (P < .001).<sup>139</sup> The significance of desmoplasia as a risk factor was confirmed by multivariable analysis. A more recent review of 72 patients with desmoplastic SCC reported a high rate of recurrence of 80%.<sup>186</sup>

Although the risk of metastasis from SCC in situ (full-thickness atypia) is negligible, the risk of recurrence, as with the superficial form of BCC, depends on the presence or absence of any of the risk factors listed in the algorithm.

**Depth**

Data from many large studies support that risk of recurrence and metastasis increases with increasing lesion depth.<sup>17,48,121,122,125,139-143,187</sup>

cSCC lesion depth can be quantified as thickness in mm or by anatomic layer(s) invaded. A standard Breslow measurement per the College of American Pathologists (CAP) 2013 protocol would be the distance from the deepest point of tumor invasion to the granular layer or base of ulcer if present,<sup>188</sup> excluding parakeratosis or scale crust.

Brantsch and colleagues<sup>126</sup> prospectively examined potential risk factors for metastasis and local recurrence of cSCC in 615 patients over a 20-year period. With a median follow-up of 43 months, metastasis occurred in 0% of tumors 2.0 mm in thickness, 4% of tumors 2.1 mm to 6.0 mm in thickness, and 16% of tumors thicker than 6.0 mm. Thicker lesions also had a higher risk of local recurrence. A large retrospective analysis and a very large meta-analysis (n = 17,248) provide data supporting that risk of recurrence and metastasis is significantly higher for lesions with thickness >2 mm.<sup>125,140,142</sup> Meta-analyses have shown that 4-mm and 6-mm thickness cutoffs are also prognostic for recurrence and metastasis,<sup>48,125</sup> and one retrospective study showed by multivariate analysis that risk for recurrence and metastasis increases significantly for every 1-mm increase in tumor depth.<sup>127</sup>

Retrospective studies and meta-analyses support that anatomic level of invasion is significantly correlated with cSCC recurrence and metastasis. Some studies showed significantly higher risk of recurrence or metastasis for cSCC lesions with Clark levels IV-V, corresponding to invasion of the deep reticular dermis or subcutaneous fat, respectively.<sup>48,139</sup> Other studies have shown that lesions with invasion into the subcutaneous fat significantly increases rates of recurrence and metastasis.<sup>17,121,122,125,141,142</sup>

Both tumor thickness and anatomic level of invasion have been included in the T classification of the AJCC 7<sup>th</sup> and 8<sup>th</sup> Edition staging for cSCC.<sup>120,129</sup>

NCCN has chosen to include both thickness and Clark level in the guidelines, and recommends that tumors  $\geq 2$  mm thick or Clark level IV-V be considered high risk. If clinical evaluation of incisional biopsy suggests that microstaging is inadequate, the panel recommends considering narrow margin excisional biopsy to obtain accurate measurement of thickness and anatomic level of invasion.

**Perineural Involvement**

Perineural involvement is uncommon in any NMSC (2%–6%), but develops more frequently and is more aggressive in cSCC versus BCC.<sup>170,171,189-192</sup> cSCC with perineural involvement poses a greatly increased risk of recurrence, metastasis (nodal and distant), and death; is more common in recurrent versus primary tumors; and is associated with other risk factors, including larger lesion size, poor differentiation, and adenosquamous (mucin producing), desmoplastic, and metaplastic (carcinosarcomatous) subtypes.<sup>17,48,121,125,131,138,141,162,165-167,186,193-196</sup> In a prospective cohort study of 315 patients with cSCC of the head and neck, Kyrgidis and colleagues identified perineural involvement as a factor associated with lower overall survival and recurrence-free survival.<sup>162</sup> Even among patients with other risk factors, PNI is an independent risk factor for lymph node metastasis, as demonstrated by multivariate analysis of a prospective study of high-risk patients.<sup>167</sup> If large nerve involvement is suspected, MRI should be considered to evaluate extent and/or rule out skull involvement in those with head and neck tumors.<sup>116,117,164,171,172,197</sup> SCC involving unnamed small nerves (<0.1 mm in caliber) may have a low risk of poor outcomes in the absence of other risk factors.<sup>122,128</sup>

**Lymphatic or Vascular Involvement**

Two prospective studies of patients with local or regional cSCC have shown significant association between lymphovascular invasion (LVI) and lymph node metastasis.<sup>144,167</sup> Retrospective studies corroborate this finding and also show that LVI is prognostic for parotid involvement.<sup>166,194</sup> One



retrospective study of 114 patients with cSCC and PNI or neurotropism showed by multivariate analysis that in this high-risk population LVI was significantly associated with disease-specific death and all-cause death.<sup>128</sup>

The presence of LVI from the primary tumor is important to note, especially in patients with other risk factors, and should increase the suspicion of subclinical nodal disease.

### Patients at High Risk of Developing Multiple SCCs

Certain patient groups are at high risk of developing multiple squamous cell skin cancers and tumors that can behave aggressively. These include individuals with an immunocompromised status, such as solid organ transplant recipients, or patients with lymphoma, chronic lymphocytic leukemia, drug-induced immunosuppression, or HIV.<sup>48,107,121,125,126,145-155,198,199</sup>

Patients with rare genetic disorders such as albinism or xeroderma pigmentosum are at high risk of developing multiple cSCCs.<sup>73-79,200</sup> Within these high-risk groups, individual high-risk patients should be identified for closer follow-up. See *Management of Patients at High Risk of Developing Multiple SCCs* for a discussion of NCCN recommendations on treatment of precancers, treatment of cSCC, prevention of cSCC, and education for patients with high risk of multiple cSCCs.

### Local Treatment for SCC

The primary goals of treatment of squamous cell skin cancer are the complete removal of the tumor and the maximal preservation of function and cosmesis. All treatment decisions should be customized to account for the particular factors present in the individual case and for the patient's preference. Localized cSCC, (ie, without clinically or radiographically concerning regional lymph nodes) is most commonly treated with surgery. Traditional techniques such as C&E are mostly supported by older studies, and data from prospective trials with long-term follow-up are limited. Although surgical approaches often offer the most effective and efficient means for accomplishing cure, consideration of function, cosmetic

outcome, and patient preference may lead to the choice of radiation therapy (RT) as primary treatment in order to achieve optimal overall results.

### Curettage and Electrodesiccation

C&E is the process of alternately scraping away tumor tissue with a curette down to a firm layer of normal dermis and denaturing the area by electrodesiccation. Up to 3 cycles may be performed in a session. Although a fast and cost-effective technique for superficial lesions, it does not allow histologic margin assessment. Retrospective and observational data with long-term follow-up (>5 y) indicate that cure rates are between 95% and 96% for patients with primary cSCC lesions treated with C&E.<sup>48,201,202</sup> These estimates are largely based on low-risk cases, and there is evidence to suggest that the cure rate is lower for tumors with risk factors. One study reported recurrence rates of 0.4% versus 11% for cSCCs with diameter less than versus greater than 2 cm, and another reported a recurrence rate of 19% for SCCs on the skin of the pinna that were treated with C&E.<sup>203,204</sup>

The NCCN panel considers this technique effective for properly selected, low-risk tumors with three caveats. First, this technique should not be used to treat areas with terminal hair growth such as the scalp, pubic or axillary regions, or beard area in males due to the risk that a tumor extending down follicular structures might not be adequately removed.

Second, if the subcutaneous layer is reached during the course of C&E, then surgical excision should generally be performed instead. This change in therapy is necessary as the effectiveness of the C&E technique rests on the ability of the clinician to distinguish between firm, normal dermis, and soft tumor tissue when using a sharp curette. Because subcutaneous adipose is even softer than tumor tissue, the ability of the curette to



distinguish, and therefore to selectively and completely remove tumor cells, disappears.

Third, if C&E has been performed based only on the appearance of a low-risk tumor, biopsy results of the tissue taken at the time of C&E should be reviewed to make sure that there are no high-risk pathologic features that would require additional therapy.

### **Excision with Postoperative Margin Assessment**

A common therapeutic option for cSCC is standard surgical excision followed by postoperative pathologic evaluation of margins. This technique has been reported to achieve 5-year disease-free rates of 91% or higher for cSCC.<sup>48,187</sup> Retrospective analyses and prospective observational studies of patients who received surgical excision of non-metastatic primary cSCC have reported rates of recurrence or metastasis ranging from 0% and 14%, with most studies reporting rates of 6% or lower.<sup>48,142,173,175,187,202,205-211</sup> Distant metastasis was rarely observed, and rates of regional metastasis (lymph node involvement), when reported separately from local recurrence, were highly variable across studies, ranging from 0% to 13%.<sup>173,175,187,205,208,211</sup> Variability in reported recurrence and metastasis rates could be due to differences in margin size, percent of patients with clear margins, length of follow-up, and the prevalence of risk factors (patient and lesion characteristics) in the populations sampled. One large meta-analysis found that post-excision recurrence rates were lower for primary tumors versus local recurrences, both for analyses with follow-up less than 5 years (5.7% vs. 17.3%) and those with longer follow-up (8.1% vs. 23.3%).<sup>48</sup>

The clinical margins chosen by the panel for low-risk tumors are based on the work of Brodland and colleagues using MMS to determine the width of clinical margin needed to achieve histologically clear margins in primary cSCCs (n = 141).<sup>212</sup> Their analysis indicated that for well-circumscribed

cSCC lesions less than 2 cm in diameter, excision with 4-mm clinical margins should result in complete removal in more than 95% of cases. For low-risk lesions >2 cm in diameter, results indicated that 6-mm margins would be needed to achieve histologically clear margins in 95% cases. For cSCCs in high-risk locations (scalp, ears, eyelids, nose, lips) or with other high-risk features (histologic grade  $\geq 2$ , invasion of subcutaneous tissue), lesions with a diameter <1 cm, 1 to 1.9 cm, and  $\geq 2$  cm would require margins of at least 4 mm, 6 mm, and 9 mm, respectively. Other retrospective analyses of cSCCs removed with MMS have reported the subclinical extension or the margin size or number of stages needed for complete histologic clearance.<sup>213-216</sup> Results from these studies further support that larger excision margins are needed as tumor diameter increases and when other risk factors are present (eg, poor differentiation, high-risk location, PNI).<sup>213-215</sup> Compared with primary tumors, recurrent tumors have larger subclinical extension and require more Mohs stages for complete removal.<sup>215,216</sup> Extensive subclinical spread was found in 14% to 15% of primary cSCCs and 23% to 50% of recurrent cSCCs.<sup>215,216</sup>

Results from retrospective and observational analyses of cSCCs removed by standard excision indicate that factors significantly associated with incomplete excision include lesion location, thickness, PNI, and invasion into the deep fascia.<sup>205,208,217-224</sup> Although results vary between studies, some of these analyses have suggested additional factors associated with incomplete excision: recurrent tumors (vs. primary), re-excision of residual primary (vs. initial excision of primary lesions), and tumor differentiation.<sup>175,218,221,224</sup> Mohs studies have shown that subclinical extension is more likely and more extensive in recurrent compared with primary cSCCs.<sup>216</sup> A few studies have indicated that incomplete excision rates vary between surgeons.<sup>219,224</sup>

As noted below, excision with comprehensive intraoperative margin control is the preferred surgical technique for high-risk cSCC. However, if



standard excision with postoperative margin assessment is used for treatment of a high-risk tumor due to patient-related clinical circumstances or other variables, wider surgical margins than those recommended for low-risk lesions must be taken and increased recurrence rates should be expected. Due to the wide variability of clinical characteristics that may define a high-risk tumor, it is not feasible to recommend a defined margin for standard excision of high-risk cSCC. Keen awareness of the subclinical extension of cSCC is advised when selecting a treatment modality without complete margin assessment for a high-risk tumor. These margins may need to be modified based on tumor- or patient-specific factors.

Any peripheral rim of erythema around a SCC must be included in what is assumed to be the tumor. For patients with positive margins from surgical excision and postoperative margin assessment, re-excision often yields clean margins, and in many cases the re-excision specimen contains no tumor cells.<sup>175,187,206,225-227</sup> Re-excision with postoperative margin assessment is therefore among the recommended treatment options for positive margins after excision of low-risk primary cSCC.

If lesions can be excised with the recommended margins, then linear closure, skin grafting, or secondary intention healing (ie, closures that do not rotate tissue around and/or alter anatomy where residual “seeds” of tumor may remain) are all appropriate reconstructive approaches.

However, if tissue rearrangement or skin graft placement is necessary to close the defect, the NCCN panel believes intraoperative surgical margin assessment is necessary before closure.

### **Mohs Micrographic Surgery or Excision with Complete Circumferential Peripheral and Deep Margin Assessment (CCPDMA)**

MMS is the preferred surgical technique for high-risk cSCC because it allows intraoperative analysis of 100% of the excision margin.

Retrospective analyses report cure rates of 96% for patients with primary cSCCs and 77% for recurrent cSCCs treated with MMS.<sup>228</sup> An extensive

meta-analysis of studies with long-term follow-up (≥5 years) reported local recurrence rates of 3.1% for primary cSCCs and 10% for recurrences treated with MMS.<sup>48</sup> Results from this meta-analysis found that cure rates for MMS depended on tumor diameter (<2 vs. ≥2 cm: 98.1% vs. 74.8%) and differentiation (well vs poorly differentiated: 97.0% vs. 67.4%), but for each of these subgroups cure rates for MMS were higher than for treatment with non-Mohs modalities.<sup>48</sup> Local recurrence rates based on long-term follow-up (≥5 years) were better for MMS compared with surgical excision, both for primary lesions (3.1% vs. 8.1%) and for recurrent lesions (10% vs. 23%).<sup>48</sup> Retrospective and prospective observational studies of localized primary cSCCs treated with MMS have reported local recurrence rates of 1.4% to 4.1% and rates of metastases between 0% and 6.3%.<sup>209,214,216,228-232</sup> Compared with primary tumors, rates of local recurrence or metastasis after MMS are higher for recurrent tumors (previously treated with a non-Mohs modality).<sup>141,216</sup> For recurrent cSCCs treated with MMS, subsequent local recurrences occurred in 5.9% to 7.7%; metastasis in 0% to 10%.<sup>209,214,216,228-231</sup> Other risk factors associated with recurrence after MMS include larger subclinical extension and more levels required for clearance.<sup>216</sup> Risk factors associated with metastasis after MMS include: size (>2 cm), Clark's level, differentiation, location in areas of prior radiation, small tumor nests and infiltrative tumor strands, single-cell infiltration, PNI, and acantholysis.<sup>141</sup>

It is not uncommon to find discrepancies between pathology results from preoperative biopsy or initial debulking compared with frozen sections taken during MMS.<sup>233-235</sup> When MMS with marginal assessment is being performed and the preoperative biopsy is considered insufficient for providing all the staging information required to properly treat the tumor, submission of the central specimen for pathologic evaluation with paraffin sections is recommended.



Excision with CCPDMA using permanent section analysis or intraoperative frozen section (IOFS) analysis is acceptable as an alternative to MMS provided that it includes a complete assessment of all deep and peripheral margins. Retrospective studies and one prospective study have reported low recurrence rates (0%–1%) for cSCC cases where histologically clear margins are achieved using this method.<sup>236</sup> It is important to note, however, that truly histologically negative margins are not necessarily achieved by IOFS alone, without CCPDMA. Both prospective and retrospective studies have reported that for cSCC tumors with negative margins upon frozen section analysis, permanent paraffin section analysis indicates positive margins in 10% to 20%.<sup>234,235,237-239</sup> One study showed that discrepancies between results from frozen versus permanent section analysis were due to unrepresentative sampling of the margins, and reported a much higher recurrence rate for IOFS cases in which permanent section showed positive margins.<sup>239</sup> The descriptive term CCPDMA underscores the panel's belief that complete assessment of all tissue margins is the key to optimal tumor removal for high-risk tumors.

### **Sentinel Lymph Node Biopsy**

Sentinel lymph node biopsy (SLNB) has been used to try to identify patients with cSCC who may be candidates for completion lymph node dissection or adjuvant RT. Prospective observational, retrospective and meta-analyses have reported that among patients with high-risk non-anogenital cSCC who underwent successful SLNB, sub-clinical nodal metastases were identified in 7% to 21%, with most studies reporting rates between 12% to 17%.<sup>123,166,167,240-247</sup> Variability in rates of sentinel lymph node (SLN) positivity is likely due to small sample size of these studies (N < 200), and differences in the type and number of high-risk factors represented in patient populations selected for SLNB. Although small sample sizes and low rates of SLN positivity limit assessment of prognostic factors, a few studies suggest that risk factors for SLNB positivity include tumor diameter and thickness, angiolymphatic invasion,

PNI, and the presence of multiple high-risk factors.<sup>166,167,245</sup> Most of these studies excluded patients with anogenital SCC, but one study reported subclinical nodal metastases in 24% of 585 patients with anogenital SCC who received successful SLNB.<sup>240</sup>

Several studies reported that among patients with localized SCC and negative SLNB results, nodal metastases were later detected in 2% to 7% of patients.<sup>123,166,167,240,242-244,246-248</sup> In addition to false negatives, in some studies there were patients with a negative SLNB who developed local recurrences or metastases outside of the previously biopsied LN basin, such that the overall rate of recurrence/metastases ranged from 7% to 12%.<sup>167,240,242</sup>

For most cSCC studies comparing outcomes for patients with a negative versus positive SLN, results show that despite receiving completion lymph node dissection, patients with a positive SLN had higher rates of postoperative recurrence/metastases, ranging from 33% to 45%.<sup>166,167,242,245</sup> Patients with a positive SLN were also more likely to die from SCC, and two studies (1 prospective, 1 retrospective) showed significantly lower 3-year disease-specific survival rate compared with SLN-negative patients.<sup>167,240,245</sup> Although these findings support that SLNB may have prognostic value, they also underscore that despite interventions for SLN-positive patients, it is unclear whether SLNB followed by completion lymph node dissection or adjuvant RT will improve patient outcomes. The criteria for selecting patients for SLNB are also unclear.

### **Radiation Therapy**

#### ***Radiation as Primary Therapy***

Although surgery is the mainstay of local treatment for SCC, patient preference and other factors may lead to the choice of RT as primary therapy for local disease without lymph node involvement. A large meta-analysis reported 5-year recurrence rates of 6.7% and 10% after RT of



primary and recurrent SCC, respectively.<sup>48</sup> Subsequent retrospective analyses on smaller samples of patients with primary cSCCs treated with first-line RT (37–233 patients) have reported a large range of recurrence rates, from 2.8% to 30%, the latter for patients with locally advanced disease (size >2 cm or deeply invasive).<sup>249-254</sup> The larger studies (n > 50) that include a cross-section of patients with primary lesions (range of sizes and T-stage) report 5-year cure rates after RT between 90% and 93% and 5-year recurrence rates between 4% and 7%.<sup>251,253-255</sup> The risk of recurrence appears to increase with increasing lesion size and T-stage.<sup>252,254,256</sup> A few small studies (n < 20) have reported that for cSCCs that have been previously treated and recurred, treatment with RT results in recurrence in 16.7% of cases.<sup>251,254</sup>

Radiation is an effective treatment option for selected patients with SCC in situ who have large or multiple lesions and those who refuse surgery.<sup>257</sup> Retrospective analyses have reported recurrence rates ranging from 0% to 10.5% in situ SCC lesions treated with RT as primary therapy, with most studies reporting local control rates near 100%.<sup>253,254,258-262</sup>

### **Adjuvant Radiation**

The value of adjuvant RT is widely debated due to lack of prospective randomized clinical trial data. For local SCC (ie, without lymph node involvement), the NCCN panel recommends adjuvant radiotherapy for any SCC that shows evidence of extensive perineural or large nerve involvement. Adjuvant RT is also a recommended option if tissue margins are positive after definitive surgery. Data supporting these recommendations are limited to retrospective studies with heterogeneous populations. In retrospective studies that included patients with SCC and PNI treated with MMS/surgery plus adjuvant RT, the results reported are for pooled populations that included patients treated with other modalities (eg, surgery/MMS alone, RT alone, chemotherapy), patients with other types of skin cancer (BCC and metatypical BCC), patients with lymph

node metastases, and a mix of patients with primary and recurrent skin lesions, with and without positive margins.<sup>168,169,195,263,264</sup> These studies suggest that postoperative RT for patients with PNI may improve local control and disease-free survival, but there is likely no survival benefit.

### **Radiotherapy Safety**

RT is often reserved for patients older than 60 years because of concerns about long-term sequelae, including secondary malignancies.<sup>159,256,259,265-276</sup> Large cohort and population-based studies (n > 1000) have shown by multivariate analysis that rates of NMSCs are significantly higher in those who received prior RT (either for a benign condition or for cancer) compared with those who have no history of therapeutic RT exposure.<sup>271-273,275</sup> In patients who developed NMSC after prior RT, most NMSC lesions occurred within the radiation field, with elevated risk of NMSC confined to the site of RT exposure. The risk of NMSC was particularly high in patients who received therapeutic RT early in life.

Radiotherapy can result in poor cosmetic outcomes, including telangiectasia, changes in skin pigmentation, and fibrosis. More serious long-term complications include non-healing ulcers; soft tissue, cartilage, bone, or brain necrosis; decreased sensation; and cataracts (for lesions in the periorbital region).<sup>254,256,259,261,268-270</sup> For SCC in situ, a few studies have reported that RT treatment can result in non-healing ulcers in up to 25% of lesions.<sup>258-260</sup>

### **Administration of Radiation**

Specifics about the application of RT, including total doses, treatment duration, and contraindications, are described under *Principles of Radiation Therapy* in the algorithm. RT is contraindicated in patients with genetic conditions predisposing to irradiation-related skin cancer (eg, basal cell nevus syndrome<sup>277-283</sup>), and relatively contraindicated in patients with connective tissue diseases (eg, lupus, scleroderma).<sup>284-287</sup> Given higher rates of poor cosmesis and complications with increasing



cumulative radiation dose,<sup>256,270,288</sup> reirradiation should not be routinely utilized for recurrent disease within a prior radiation field. As described in the previous section, RT is often reserved for patients >60 years of age due to concerns about risk of RT-related subsequent malignancies.

Protracted fractionation is associated with improved cosmetic results,<sup>268,270,289-291</sup> and should be utilized for poorly vascularized or cartilaginous areas. Retrospective studies have found that for patients with cSCC and PNI, failures tend to occur along involved nerves, suggesting that extending the radiation field along involved nerves may help reduce risk of recurrence.<sup>169,292,293</sup> The NCCN panel recommends that for extensive PNI, clinically evident perineural involvement, or involvement of named nerves, (particularly in the head and neck region), consider including the course of the local nerves proximally.

Selection of target area margins and RT modality is left to clinical judgement and based on the experience and expertise available at the treating institution. A variety of external beam options have been shown to be effective for treating cSCC and have similar cosmetic/safety results,<sup>256,270,289,294-296</sup> and are generally accepted as standard of care.

Brachytherapy, however, is not considered a standard-of-care approach for treatment of skin cancer. There are insufficient long-term efficacy and safety data to support the routine use of electronic surface brachytherapy, and radioisotope brachytherapy should only be considered in highly selected cases.

### Superficial Therapies

Given the limited penetration beyond epidermis and lower cure rates than with surgical techniques, superficial therapies should be reserved for those patients with SCC in situ.<sup>297-299</sup> Recommended superficial therapies include topical fluorouracil (5-FU), topical imiquimod, photodynamic therapy (PDT), and cryotherapy.

### Topical Therapies

Retrospective studies, meta-analyses, and an open-label phase II trial have shown that imiquimod was effective for treating patients with SCC in situ, with reasonably high rates of initial clearance (70%–100%) and low rates of recurrence.<sup>300-305</sup> One small (n = 31) double-blind randomized trial showed that imiquimod led to the resolution of 73% of lesions compared to 0% of lesions resolving with vehicle control ( $P < .001$ ).<sup>306</sup> Side effects include inflammatory skin reactions, such as erythema, pruritus, and pain, and often lead to discontinuation of imiquimod before the treatment course is complete.<sup>302,304</sup> Discontinuation after lesion clearance has not been shown to lead to recurrence.

5-FU is another agent used topically to treat SCC in situ. Clearance rates with 5-FU tend to be lower than those for topical imiquimod, and vary widely, ranging from 27% to 93%.<sup>302,305,307-309</sup> Toxicities are similar to imiquimod, being primarily inflammatory skin reactions such as severe eczematous reactions, ulceration, and erosions.<sup>302,308,309</sup>

### Cryosurgery/Cryotherapy

Cryosurgery, which destroys tumor cells by freeze-thaw cycles, has been used for many years as a fast and cost-effective means for removal of SCCs. Prospective and retrospective studies, including large meta-analyses, have shown recurrence rates of 0% to 4% for invasive SCCs treated with cryotherapy.<sup>48,310-313</sup> For SCC in situ, recurrence rates after cryotherapy range from 1% to 13% in retrospective studies<sup>258,298,299,313</sup> and 0% to 50% in prospective studies.<sup>297,309,312,314,315</sup> Variability in reported recurrence rates may be due in part to patient selection, variable follow-up durations, and differences in technique and operator skill. Common adverse events associated with cryosurgery include edema/blistering, scabbing, ulceration, loss of pigment, and postoperative pain.<sup>297,314,316</sup> Less common adverse events include scarring and infection.<sup>297,312,314-316</sup> One prospective comparative study reported that patients were much more



likely to experience pain with cryotherapy compared with curettage and cautery, and time to complete healing was also significantly longer with cryotherapy.<sup>297</sup> A randomized controlled trial showed that cryotherapy was associated with poorer cosmetic outcomes compared with topical 5-FU for treatment of SCC in situ.<sup>309</sup>

### **Photodynamic Therapy**

PDT involves the application of a photosensitizing agent on the skin followed by irradiation with a light source. Photosensitizing agents often used include methyl aminolevulinate (MAL) and 5-aminolevulinic acid (ALA). For SCC in situ, rates of initial complete clearance following PDT with ALA or MAL range between 52% and 98% according to prospective studies (n = 23–96 lesions).<sup>308,317-328</sup> Most of these studies report recurrences, such that durable complete response rates range from 48% to 89%.<sup>308,309,317-320,322-326,328,329</sup> Small randomized trials have shown that differences in PDT techniques can cause significant differences in clearance rate for SCC in situ,<sup>318,326</sup> which likely contributes to the broad range of rates reported in the literature. One small randomized trial showed that fewer treatments were required for complete clearance with PDT versus cryotherapy, and two randomized trials showed that durable complete response rates were higher with PDT.<sup>309,314</sup> Another small randomized trial in patients with SCC in situ showed that PDT was associated with higher rates of initial complete clearance compared with 5-FU, and two randomized trials showed that and durable complete response rates were higher with PDT.<sup>308,309</sup>

PDT is associated with itching, tingling, stinging, burning during the application of the topical agent, and mild to moderate pain during the phototreatment.<sup>318-323,325,330,331</sup> Other less common toxicities include severe pain, ulceration, crusting, edema, erythema, scarring, and pigmentary alterations.<sup>320-323,325,331-333</sup> Most of these resolve within days or weeks of

treatment, but there have been reports of long-term scarring and pigmentary alterations.

Results from randomized trials in patients with SCC in situ suggest that 5-FU may be associated with lower risk of adverse events compared with PDT or cryotherapy, but due to inconsistent results across trials it is unclear whether risk of toxicity differs between cryotherapy and PDT.<sup>308,309,314</sup> All three treatment modalities are associated with risk of pain and various manifestations of inflammation at the treated site, including erythema, burning, crusting, stinging, itching, edema/blistering, and ulceration/erosions. All three also occasionally lead to pigmentary changes, or scarring.

Currently, PDT is being utilized at some NCCN Member Institutions for SCC in situ lesions. Although MAL is an approved photosensitizer for PDT, it is no longer produced in the United States.

### **Systemic Therapy for Local High-Risk SCC**

Case reports and a few small studies have reported results for patients with high-risk, localized, nonmetastatic cSCC treated with chemotherapy or radiochemotherapy.<sup>334-345</sup> Most of these studies included patients with large, deeply invasive primary tumors that were unlikely to be cured by surgery or RT.<sup>334,338-340,342-344</sup> A few studies reported results from patients with operable disease who refused surgery or with residual disease after surgery.<sup>337,341,342</sup> Results show that some patients with locally advanced non-metastatic cSCC respond to cytotoxic therapy.<sup>337-339,341-344</sup> Epidermal growth factor receptor (EGFR) inhibitors such as cetuximab have also been tested in a small number of patients with nonmetastatic locally advanced disease, and responses have been reported.<sup>346-352</sup> In the absence of data from prospective comparative studies, however, it is unclear which systemic therapies are appropriate for localized disease in cases where surgery is not possible, especially in the context of



concomitant RT. In contrast, large randomized trials have tested systemic therapy options for head and neck mucosal SCCs. Therefore, for the rare cases of localized high-risk SCC in which chemoradiation is considered, the NCCN panel recommends referring to the systemic therapy options recommended for mucosal SCC in the NCCN Guidelines for Head and Neck Cancers.

### **NCCN Recommendations for Treating Local SCC**

For patients with SCC presenting with palpable or abnormal lymph nodes, please see *Regional Lymph Node Involvement in SCC*.

#### **Low-Risk Local SCC**

Primary treatment options for low-risk local SCC include: 1) C&E in areas without hair growth (ie, excluding terminal hair-bearing regions, such as the scalp, pubic and axillary regions, and beard area in men), provided that the treatment be changed to excision if the adipose tissue is reached; 2) standard excision if the lesion can be excised with 4- to 6-mm clinical margins and repaired with linear closure, secondary intention healing, or skin graft; and 3) RT for non-surgical candidates, generally limited to those older than 60 years of age because of risk of long-term toxicity.

If margins are positive after excision, patients should receive additional therapy. MMS, resection with CCPDMA with frozen or permanent section, or standard re-excision for area L regions (trunk and extremities, excluding pretibia, hands, feet, nail units, and ankle) are recommended, while radiation may be administered to non-surgical candidates.

The NCCN panel discussed the use of alternative therapies for first-line treatment in patients with SCC in situ (Bowen's disease). Although cure rates may be lower than with surgical treatment modalities, alternative therapies the panel recommends considering include 5-FU, imiquimod, PDT with porfimer sodium or ALA, or vigorous cryotherapy. Data suggest that the cure rates of these approaches may be lower compared with

surgery.<sup>297-299</sup> On the other hand, panelist experience indicates that they may be effective for anatomically challenging locations, and recurrences are often small and manageable.

#### **High-Risk Local SCC**

Recommended options for high-risk lesions include: 1) standard excision, using wider margins with linear or delayed repair; 2) MMS or resection with CCPDMA with frozen or permanent section; and 3) RT for non-surgical candidates.

Due to the wide variability of clinical characteristics that may define a high-risk tumor, it is not feasible to recommend a defined margin for standard excision of high-risk SCC. Keen awareness of the subclinical extension of SCC is advised when selecting a treatment modality without complete margin assessment for a high-risk tumor. These margins may need to be modified based on tumor- or patient-specific factors. If negative margins are not achieved after standard excision, patients should undergo MMS or resection with CCPDMA, or receive RT. If residual disease is still present after second-line treatment and further surgery is contraindicated, the NCCN panel recommends a multidisciplinary consultation to consider chemoradiation or clinical trial.

Similarly, patients treated with MMS or resection with CCPDMA as first-line therapy should receive subsequent therapy if clear margins cannot be achieved. Recommended options include radiation (of primary site) and/or multidisciplinary consultation to consider chemoradiation or clinical trial. Appropriate chemotherapy agents can be found in the NCCN Guidelines for Head and Neck Cancers. If invasion into parotid fascia is discovered during MMS or resection with CCPDMA, then superficial parotidectomy is indicated.

Adjuvant RT to the primary site is recommended for patients with negative margins after surgery if there is large nerve or extensive perineural



involvement. Due to the potential for skull involvement and intracranial extension, an MRI with contrast of the area of interest should be considered if large-nerve invasion is suspected for tumors on the head and neck.

For certain high-risk SCCs, SLNB mapping may be considered. A systematic review of 692 patients with SCC reported positive sentinel nodes in 24% and 21% of anogenital and non-anogenital patients, respectively.<sup>240</sup> The survival benefit of and indication for SLNB remains unclear.

### Management of Patients at High Risk of Developing Multiple SCCs

As described in the section entitled *Patients at High Risk of Developing Multiple cSCCs*, certain patient groups are at high risk of developing multiple squamous cell skin cancers and tumors that can behave aggressively. This section describes considerations and recommendations for management of these patients.

### Treatment of Precancers in High-risk Patients

Actinic keratoses are a premalignant skin condition that should be treated at first development, particularly in patients with diffuse actinic keratoses and/or field cancerization, as these patients are at high risk of developing multiple primary cSCCs. C&E and cryotherapy have been used to treat actinic keratosis for many decades, despite lack of prospective randomized trials comparing them with placebo. In more recent years large prospective randomized trials in patients with actinic keratoses ( $n > 100$ ) have shown that each of the following therapies provides better complete clearance rates compared with placebo: topical 5-FU,<sup>353-357</sup> topical imiquimod,<sup>358-361</sup> topical ingenol mebutate,<sup>362-364</sup> and PDT (either with ALA or MAL).<sup>365-372 373,374</sup> The utility of topical diclofenac is less clear, as efficacy results vary across large randomized trials testing topical

diclofenac in hyaluronan, with some studies reporting no significant difference from hyaluronan alone.<sup>357,375-377</sup> Large randomized trials have also shown that diclofenac/hyaluronan is inferior to MAL-PDT and to 5-FU for the treatment of actinic keratoses.<sup>378,379</sup> The panel therefore assigns category 2B for diclofenac in this setting.

For the commonly used treatments known to be effective at clearing actinic keratoses (cryosurgery, PDT, 5-FU, and imiquimod), prospective randomized trials, including some intraindividual studies, have reported pair-wise comparisons, but results are not entirely consistent. For example, large randomized trials comparing PDT with cryotherapy have shown better cosmetic outcomes for PDT, but efficacy results vary across studies.<sup>365,367,370,380-382</sup> Other treatments directly compared in prospective randomized trials include PDT compared with imiquimod,<sup>383,384</sup> 5-FU,<sup>385-387</sup> or ingenol mebutate,<sup>388-390</sup> cryotherapy compared with 5-FU or imiquimod,<sup>391-393</sup> and 5-FU compared with imiquimod<sup>394</sup> or ingenol mebutate.<sup>395,396</sup> Meta-analyses of RCTs have attempted to determine an order of preference among the commonly used treatments for actinic keratosis. A meta-analysis of 32 prospective randomized trials reporting short-term (<1 y) rates of complete clearance (by patient) derived the following efficacy ranking: 5-FU 5% > 5-FU 0.5% > ALA-PDT ≈ imiquimod ≈ ingenol mebutate ≈ MAL-PDT > cryotherapy > diclofenac /hyaluronan > placebo.<sup>373</sup> Given the complexity of comparing so many treatment options, the NCCN panel considers cryotherapy, topical 5-FU, topical imiquimod, topical ingenol mebutate, PDT, and C&E to all be reasonable options for treating actinic keratosis.

Fewer high-quality data are available regarding the efficacy and safety of several other treatments that are sometimes used and may be considered for treating actinic keratoses: chemical peels (trichloroacetic acid) and ablative skin resurfacing (eg, dermabrasion, laser).<sup>397-404</sup> These studies have all confirmed that laser resurfacing or chemical peel significantly



reduced the quantity of actinic keratoses, although in some studies they were less effective than PDT or 5-FU. The use of chemical peels and ablative skin resurfacing varies widely across NCCN institutions.

Actinic keratoses that have an atypical clinical appearance or do not respond to appropriate therapy should be biopsied for histologic evaluation.

Actinic keratosis on the lip, known as actinic cheilitis, may require a different approach. Prospective studies on the treatment of actinic cheilitis are limited, and most of these studies are small and noncomparative. Therapies tested in this setting include surgical vermilionectomy, lip shave, electrodesiccation, laser vermilion ablation, laser resurfacing, 5-FU, laser + 5-FU, trichloroacetic acid (TCA) chemical peel, PDT, PDT + imiquimod, and diclofenac.<sup>405-416</sup> The NCCN panel considers ablative laser vermilionectomy to be of value for treating some cases of extensive actinic cheilitis.

### **Treatment of SCC in High-Risk Patients**

For individuals who rapidly develop multiple cSCC lesions, destructive techniques that can be used to treat multiple lesions in a single visit may be preferable. Examples of appropriate destructive techniques include C&E and cryotherapy. If C&E has been performed based solely on the clinical appearance of a low-risk tumor, the pathology from the biopsy taken at the time of C&E should be reviewed to make sure there are no high-risk pathologic features that would suggest the need for further therapy. Some NCCN panel members use a combination of shave excision to remove the bulk of the tumor and ensure sufficient material for pathology, and then destructive techniques for margin control. The details of the techniques used to remove cSCC lesions in high-risk patients with multiple lesions vary widely between NCCN Member Institutions and between practitioners at these institutions, and there is no standard

language for describing these methods. In patients who develop multiple adjacent tumors in close proximity, if surgical excision of invasive disease does not include surrounding in situ disease then tissue rearrangement should be minimized so that the remaining in situ disease can be treated with secondary approaches.

Compared to the low-risk population, RT is used more frequently as an adjuvant therapy in high-risk patients and for perineural disease.<sup>417</sup> Satellite lesions and in-transit cutaneous metastases may occur more frequently and are more likely to progress in this population.<sup>418,419</sup> cSCC can progress quickly in high-risk patients with satellite or in-transit metastasis, so these patients must be treated aggressively with multidisciplinary tumor board consultation.

One feasible strategy for cases of life-threatening skin cancer or rapid development of multiple tumors in organ transplant recipients is dose reduction of immunosuppressive therapy and/or the use of mTOR inhibition. Multivariate analyses of large populations of organ transplant patients have found that the incidence of new skin cancers is linked to the duration and dose of immunosuppression.<sup>420-422</sup> Prospective randomized trials in transplant patients have shown that switching from other immunosuppressants to mTOR inhibitors reduces the risk of developing new cSCC lesions, particularly in patients with a history of one or more cSCCs.<sup>423-431</sup> In the case where surgery is impractical due to high cSCC burden, oral capecitabine has been suggested in the transplantation setting, although toxicity is a concern.<sup>432</sup>

### **Prevention in High-Risk Patients**

Treatment of precancers at first development can help prevent the development of subsequent invasive tumors, but prophylactic treatment may be needed for patients who have a history of multiple lesions and/or extensive diffuse actinic keratosis or field cancerization. Oral retinol and



synthetic retinoids (eg, acitretin, isotretinoin, etretinate) have been tested in prospective studies in patients at high risk for multiple actinic keratoses or SCCs, including transplant recipients,<sup>433-438</sup> patients with xeroderma pigmentosa,<sup>439</sup> or with psoriasis and PUVA (psoralen plus UV-A) exposure.<sup>440</sup> By comparison with placebo or with SCC incident rates during treatment-free periods, data from these studies support that oral retinol and oral retinoids significantly reduce the incidence of new cSCCs in these patients at very high risk for multiple lesions.<sup>434-437,439,440</sup>

Outside of these very-high-risk groups the effectiveness of retinol/retinoid therapy for prophylaxis is less clear. Several large prospective randomized trials have evaluated the impact of oral retinol or retinoids on development of new actinic keratoses or NMSCs in patients with multiple prior lesions but no major predisposing factors such as transplant or genetic disease. The SKICAP-AK double-blind randomized trial showed that for 2297 patients with 10 or more prior actinic keratoses (at least 1 in the past year) but no more than 2 prior SCC/BCC lesions, the hazard ratio (HR) for developing a new SCC was 0.74 (95% CI, 0.56–0.99;  $P = .04$ ) for oral retinol compared with placebo, but the probability of developing a new BCC was not different across treatment arms.<sup>441</sup> The SKICAP-BCC/SCC double-blind randomized trial compared oral retinol ( $n = 173$ ) and isotretinoin ( $n = 178$ ) with placebo ( $n = 174$ ) in patients with at least 4 prior BCCs and/or SCCs and the most recent tumor diagnosed in the past year.<sup>442</sup> Results showed a similar number of new BCCs and new SCCs across all three treatment arms, and no significant difference in time to first new lesion. In another randomized trial, 70 nontransplant patients with at least 2 prior BCCs/SCCs were randomized to receive either oral acitretin or placebo for 2 years.<sup>443</sup> Although there was a trend toward fewer patients with new NMSCs on acitretin (19 [54%] vs. 26 [74%] for placebo), the effect was not statistically significant, and the level of actinic damage was not affected.

Side effects associated with oral retinoids may be significant. Most adverse events are mucocutaneous, such as cheilitis, excessive peeling of the skin, and hair disorders,<sup>438</sup> but musculoskeletal, vascular, hepatic triglyceride, and neurologic (eg, emotional, headaches) adverse events have also been reported.<sup>437,439,442,444</sup> In addition, these agents are teratogenic and must be used with extreme caution in women of child-bearing age.<sup>445-447</sup> To determine whether these side effects could be avoided, the topical tretinoin cream (0.1%) was compared with vehicle control in a large randomized trial ( $N = 1131$ ) in patients with at least 2 prior BCC or SCC lesions in the previous 5 years (but free of disease at baseline).<sup>448</sup> Patients at very high risk for recurrence were excluded (eg, xeroderma pigmentosum, prior RT, organ transplant, arsenic exposure, prior PUVA-PDT). Unfortunately, after a follow-up of 1.5 to 5 years, there was no significant difference between treatment arms for any of the metrics related to development of new invasive or in situ SCCs, BCCs, or total number of actinic keratoses.

The NCCN guidelines do *not* recommend topical retinoids as prophylactic treatment for patients at high risk for multiple actinic keratoses or cSCCs. Results of a large randomized trial in patients with a history of  $\geq 2$  BCCs/SCCs showed that prophylactic topical tretinoin (0.1%) did not reduce the development of new cutaneous BCCs or SCCs compared with vehicle control.<sup>448</sup> A double-blind randomized cross-over study showed that topical tazarotene had a chemopreventative effect in only 6% (1/27) of patients with basal cell nevus syndrome, a condition associated with frequent development of primary BCCs.<sup>449</sup>

Results from a recent randomized controlled study suggest that prophylactic nicotinamide may be effective at preventing the development of cSCC recurrence or metastases in patients at high risk.<sup>450</sup> Patients with a NMSC in the past 5 years were randomized to either placebo or oral nicotinamide 500 mg BID ( $n = 193$  patients per arm) for 12 months,



followed by 6 months off the study drug. After 12 months of treatment the rate of new NMSCs was 23% lower ( $P = .02$ ), as was the number of actinic keratoses (13% lower,  $P = .001$ ). Nicotinamide was associated with a 30% reduction in the 12-month rate of new SCCs ( $P = .05$ ), and a 20% reduction in development of new BCCs ( $P = .12$ ). Safety signals did not differ significantly between study arms. During the subsequent 6 months off treatment there was a trend toward increased rates of new SCCs for the nicotinamide arm compared with placebo (59% relative difference;  $P = .07$ ). Although there are currently no clinical trial data directly comparing nicotinamide with oral retinoids for cSCC prophylaxis, nicotinamide has a much better safety profile. Further clinical research is needed to determine whether nicotinamide provides long-term clinical benefit for patients at risk of developing multiple NMSC and AK lesions.

Celecoxib, an inhibitor of cyclooxygenase 2 (COX-2), has been tested in randomized trials as a chemopreventative measure for reducing the development of precancers and NMSCs in patients at high risk.<sup>451</sup> A phase II-III randomized double-blind trial found that compared with placebo, oral celecoxib did not reduce the rate of new actinic keratoses, but did significantly reduce the rate of new BCCs and new cSCCs in patients with numerous actinic keratoses ( $n = 10$ – $40$  lesions per patient).<sup>451</sup> However, a meta-analysis of data from this trial and two large case-control studies<sup>452,453</sup> found that skin cancer incidence was not lowered by celecoxib.<sup>454</sup> The phase II-III trial did not find increased risk of cardiovascular adverse events with celecoxib versus placebo, but studies comparing celecoxib with placebo in other clinical settings showed significantly increased risk of serious and sometimes fatal cardiovascular and gastrointestinal (GI) toxicities.<sup>455,456</sup> The prescribing information for celecoxib includes a blackbox warning that celecoxib is associated with increased risk of serious cardiovascular thrombotic events, including stroke and myocardial infarction, and increases risk of serious GI adverse events including GI bleeding, ulceration, and perforation.<sup>457</sup> Due to safety concerns the NCCN

panel does not recommend celecoxib for prevention of actinic keratoses, cSCC or BCC.

### Patient Education for High-Risk Patients

Patient education is especially important for those at high risk for cSCC progression or recurrence. A primary goal of patient education is to facilitate early detection and rapid entrance into the health care delivery system at the onset of tumor development, as early treatment is critical for preventing development of metastatic disease. Treatment delay is associated with larger tumor size, larger defect size from surgical removal, and more Mohs layers taken to obtain clear margins.<sup>174,458-461</sup> Significant prognostic factors for patient delay in seeking care include serious comorbidity, low education level, non-recognition of the seriousness of symptoms, and SCC arising on pre-existing chronic lesions.<sup>462,463</sup> Low education level is also associated with large NMSC tumor area at presentation.<sup>464</sup> Educational interventions and advice given by physicians have been shown to increase the likelihood of patients undergoing a complete skin exam, and patients with more knowledge of skin cancer are more likely to get regular complete skin exams.<sup>465-467</sup>

Patient education should begin, in the case of organ transplant recipients, at transplantation and in the case of xeroderma pigmentosum, at birth or diagnosis. Education should include discussion of individual risk assessment and the need for stringent sun avoidance and protection methods to prevent development of further disease. Prospective randomized trials have shown that regular sunscreen use (compared with use at patient's discretion) significantly reduces the rate of development of new actinic keratoses and cSCCs, and increases remission rates of actinic keratoses.<sup>468-471</sup>

Both extensive and repetitive patient education regarding sun avoidance and protection is required. Having a prior NMSC has proved to be



insufficient motivation for altering patient behavior regarding UV protection and avoidance. A recent survey of over 30,000 non-Hispanic white adults in the United States showed that although those with prior NMSC are more likely to use sunscreen and to avoid sun exposure (compared to those without prior NMSC), adoption of preventative measures was low: only 54% used sunscreen, and 20% to 45% used other avoidance/protective methods.<sup>472</sup> Among those with prior NMSC, 30% had experienced a recent sunburn. Another cross-sectional study in the United States based on a survey of >14,400 non-Hispanic white adults showed that tanning bed use was similar among those with and without prior NMSC.<sup>473</sup>

Education has been shown to effect change in preventative behaviors. Randomized trials have shown that educational interventions can effect significant changes in use of solar protection in outdoor workers and transplant patients.<sup>467,474-477</sup> A prospective randomized trial comparing educational interventions showed that while both extensive and repetitive education improves patient knowledge of skin cancer risks and appropriate methods for UV protection, repetitive education is needed to effect long-term change in patient behavior.<sup>478</sup> Repeated educational interventions are especially important for transplant patients, as preoccupation with other medical concerns may make them unreceptive to skin cancer education, especially during the first year after receiving their transplant.<sup>479</sup> One randomized trial in transplant patients showed that an intervention including text messaging reminders was more effective at improving patient knowledge and changing sun protective behaviors compared with more traditional education approaches.<sup>480</sup> Knowledge of more than one method for UV protection is associated with higher rates of using some form of protection,<sup>481</sup> as is awareness of susceptibility/risk and overall education level.<sup>482,483</sup> Among transplant patients, use of photoprotective measures was higher among those seen at a specialist organ transplant dermatology clinic.<sup>484</sup> Those least likely to know or follow

preventative methods are young people, men, members of lower socioeconomic class, or those with lower education level.<sup>485</sup>

Monthly self-examination is recommended, and should include all skin surfaces and lymph nodes. Patients should be taught the proper method for systematic self-examination of the skin and lymph nodes. A randomized controlled trial has shown that educational intervention increased the frequency and sensitivity of self-examination of the skin among transplant patients.<sup>486</sup> In addition to more frequent and thorough self-examination, follow-up schedules for patients at high risk should be titrated to the frequency of tumor development, and in rare cases may be as frequently as weekly.

### **Regional Lymph Node Involvement in SCC**

For patients with SCC, regional nodal involvement significantly increases the risk of recurrence and mortality.<sup>50,140,143</sup> Nodal metastasis also commonly coincides with other adverse histopathologic findings such as LVI, poor differentiation, and PNI.<sup>17,121,122,131,140,141,143,144</sup> About 60% to 82% of patients presenting with nodal disease show involvement in the parotid gland, while cervical neck node disease without parotid invasion is observed in 18% to 41% of cases.<sup>487</sup>

### **NCCN Recommendations for Workup for Suspicion of Regional Lymph Node Involvement**

The presence of palpable regional lymph nodes or suspicious lymph nodes identified by imaging studies should prompt an FNA or core biopsy of suspicious node(s). If initial pathology results are negative, the NCCN panel recommends considering re-evaluation by clinical exam, CT with contrast imaging of the nodal basin, and/or pathology on additional LN specimens taken by repeat FNA, core biopsy, or open biopsy of the suspicious node(s). For patients with pathologic evidence of LN disease, preoperative imaging of the nodal basin by CT with contrast is



recommended to determine the size, number, and location of involved nodes. PET/CT of the nodal basin can be useful for RT planning. In addition, chest/abdominal/pelvic CT with contrast or PET/CT are recommended as clinically indicated to rule out distant metastatic disease.

### **Treatment of SCC with Regional Lymph Node Involvement**

Data on SCC with nodal metastasis are limited to retrospective or observational studies. Some of these studies have shown that treating regional disease with RT alone results in poorer survival and/or regional/local control than those who received surgery plus adjuvant RT.<sup>145,488-491</sup> This was true for patients with parotid involvement, neck lymph node metastases, or a combination of the two, which is why the NCCN panel recommends resection of regional disease over radiation or chemotherapy. Radiation with or without concurrent therapy is reserved for patients who are not surgical candidates.

Most studies of patients with regional involvement of cSCC focus on treatment of parotid and/or cervical nodes either with surgery alone (parotidectomy and/or neck dissection) or surgery plus adjuvant radiotherapy.<sup>51,145-149,151,152,488-507</sup> In these studies the extent of resection and whether adjuvant RT was given depended on the treating clinician's assessment of the extent of the disease and risk of recurrence. Although some institutions have standard practices guiding treatment, published data from studies at these institutions may include cases in which the clinician deviated from that standard practice. Many of these studies used highly heterogeneous patient populations, including a wide range of levels of lymphatic and/or parotid involvement, a mix of primary and recurrent disease, and a mix of immunosuppressed and immunocompetent patients. In addition, some studies included a few patients treated with adjuvant chemotherapy,<sup>147-149,494,500-502,507</sup> and a few included patients who received RT or chemotherapy alone (no surgery).<sup>51,145,489-492</sup>

For studies where the majority of patients receive at least surgery plus adjuvant RT for parotid and/or neck LN metastases, recurrence rates are usually between 20% to 35%,<sup>145-147,149,488,491,493,494,496,497,506,507</sup> and estimates of 5-year disease-free survival and disease-specific survival are between 59% to 83%<sup>147,149,151,500</sup> and 63% to 83%,<sup>145,148,149,151,152,488,489,491-497,499</sup>, respectively.

Due to the heterogeneity of study populations and treatment selection bias in these retrospective/observational studies, direct comparison of treatment outcomes is not appropriate. However, multivariate analyses provide some insight into factors and treatment options associated with better outcomes.

Studies of patients with cSCC metastases to the parotid and/or lymph nodes in the neck from several Australian centers (ie, Royal Prince Alfred Hospital, Westmead Hospital, Peter MacCallum Cancer Centre) have found by multivariate analysis that adjuvant RT improved local regional control or disease-free survival.<sup>493,497,501</sup> This finding was corroborated by a study from University of Texas Southwestern Medical Center.<sup>503</sup> Another study from Westmead Hospital that included patients with LN metastases of the neck but excluded those with parotid involvement found by multivariate analysis that adjuvant RT improved disease-free survival.<sup>147</sup> In contrast, studies from 2 different centers (ie, Toowoomba Hospital, Greenlane Hospital) found no significant association between adjuvant RT and improved disease-free survival or recurrence rate in patients with involvement of the parotid and/or cervical nodes.<sup>149,150</sup> Survival results are also mixed. Whereas several studies showed by multivariate analysis that adjuvant RT improved overall survival in patients with parotid and/or neck lymph node involvement,<sup>146,151,501,505</sup> and one study showed that this was also true for the subset of patients with neck lymph node involvement alone (no parotid involvement),<sup>147</sup> data from the Royal Prince Alfred

Hospital showed no significant association between adjuvant RT and overall survival.<sup>494</sup>

Such variability in results across studies suggests that there may be subsets of patients who derive more clinical benefit from adjuvant RT than other patients. Based on these retrospective and observational analyses, it is difficult to determine distinguishing features for identifying patients most likely to derive clinical benefit from adjuvant RT. Adjuvant RT is therefore a recommended option for all patients following resection of regional cSCC.

Many retrospective and observational studies have attempted to identify prognostic factors and determine how to best risk stratify patients with regional cSCC. Even among studies with multivariate analyses, results vary for all of the prognostic factors frequently considered, including patient characteristics (age, current/prior immunosuppression), features of the primary tumor (size, LVI, PNI, differentiation, positive margins after excision), and features of the regional disease (LN size, extracapsular extension (ECE), number of involved nodes, involvement of parotid, neck nodes, or both).<sup>145-149,151,152,488,489,492-494,499,501,505,508</sup> For each of these there are some analyses showing that they are significantly associated with regional control or survival, and other analyses showing no significant association.

Several staging systems have been proposed for regional cSCC, as shown in Table 1. O'Brien proposed a staging system that separated parotid involvement from neck LN involvement based on multivariate analysis showing improved local control for P1 compared with P2/P3.<sup>493</sup> Multivariate analysis of 126 patients corroborated the finding that P2/P3

were associated with reduced locoregional control,<sup>145</sup> but two other multivariate analyses found that P-stage was not significantly associated with disease-free survival.<sup>489,500</sup> Results from multivariate analyses of survival also yielded mixed results regarding the prognostic value of O'Brien P-stage.<sup>145,146,151,152,493,500</sup> O'Brien also showed by multivariate analysis that survival was significantly better for patients with N0/N1 compared with N2.<sup>493</sup> One other multivariate analysis (n = 170) supported this result,<sup>151</sup> but several other multivariate analyses did not find a significant association with survival or locoregional control.<sup>145,146,152,489,500</sup>

The AJCC 7<sup>th</sup> edition staging for regional cSCC reflects the results from multiple studies, and therefore does not separate parotid from cervical lymph node involvement. The AJCC 7<sup>th</sup> edition staging includes both 3-cm and 6-cm cutoffs for largest lymph node dimension. A subsequent analysis by Forest and colleagues in 2010 found that lymph node size was related to ECE, and that the 3-cm cutoff was significantly associated with survival as long as ECE was excluded from the model.<sup>494</sup> Their multivariate analysis did not confirm the 6-cm cutoff, so they proposed a new staging system that only includes the 3-cm cutoff. Risk stratification per the NCCN Guidelines takes into account data from multivariate analyses showing that ECE and margin status after resection are prognostic for recurrence and/or survival.<sup>146,489,493,499,500,508</sup> The recent update of the AJCC staging system also now includes extranodal extension as a criterion for determining N-stage.<sup>129</sup> It should be noted that there are other multivariate analyses that showed no significant association between outcomes and ECE or margin status.<sup>151,489,500,501</sup>

**Table 1. Staging Systems for Regional Cutaneous SCC of the Head and Neck**

O'Brien 2002 Staging System <sup>493</sup>	
Parotid Stage	
Stage	Criteria
P1	1 LN+ ≤3 cm
P2	1 LN+ >3 and ≤6 cm or ≥2 LN+
P3	1 LN+ >6 cm or Involves VII nerve or skull base
Neck Stage	
Stage	Criteria
N0	No clinical neck disease
N1	1 LN+ ≤3 cm ipsilateral
N2	1 LN+ >3 cm or ≥2 LN+ or ≥1 LN+ contralateral

AJCC 7 <sup>th</sup> Edition (2009) Regional LN Staging <sup>119</sup>	
Stage	Criteria
N1	1 LN+ ≤3 cm ipsilateral
N2a	1 LN+ >3 and ≤6 cm ipsilateral
N2b	≥2 LN+ all ≤6 cm ipsilateral
N2c	≥1 LN+ ≤6 cm bilateral/contralateral
N3	≥1 LN+ >6 cm

AJCC 8 <sup>th</sup> Edition (2017) Regional LN Pathological Staging <sup>129</sup>	
Stage	Criteria <sup>a</sup>
N1	1 LN+ ≤3 cm ENE(-)
N2a	1 LN+, >3 and ≤6 cm ipsilateral ENE(-) or 1 LN+ ≤3 cm ipsilateral ENE(+)
N2b	≥2 LN+ all ≤6 cm ipsilateral ENE(-)
N2c	≥1 LN+ all ≤6 cm bilateral/contralateral ENE(-)
N3a	≥1 LN+ >6 cm ENE(-)
N3b	1 LN+ ≤3 cm ENE(+) contralateral, or ≥1 LN+ >3 cm ipsilateral ENE(+) or ≥2 LN+, any ENE(+)

Forest 2010 N1S3 Staging System <sup>494</sup>	
Stage	Criteria
I	1 LN+ ≤3 cm
II	1 LN+ >3 cm or ≥2 LN+ ≤3 cm
III	≥2 LN+ >3 cm

NCCN Guidelines	
Risk Level	Criteria
Low	1 LN+ ≤3 cm, no ECE
Medium	1 LN+ >3 cm no ECE or ≥2 LN+ no ECE
High	≥1 LN+ with ECE or Incompletely excised disease

ECE, extracapsular extension; ENE(+), with extranodal extension; ENE(-), without extranodal extension; LN+, positive lymph node(s)

<sup>a</sup>Pathologic criteria



### Systemic Therapy for Regional Disease

Regional cSCC has been shown to respond to systemic cytotoxic therapies and to EGFR inhibitors in a number of prospective (noncomparative) and retrospective studies.<sup>341,343,352,509-512</sup> However, in the absence of prospective comparative trial data it is unclear whether these systemic therapies provide additional clinical benefit when used postoperatively in combination with RT. Several retrospective studies were unable to show that the addition of chemotherapy to postoperative RT significantly improved any disease-related outcome in patients with regional disease,<sup>148,508</sup> but at least one retrospective study showed improved relapse-free survival by multivariate analysis.<sup>345</sup>

A wide variety of cytotoxic therapies have been tested in patients with regional or distant metastatic cSCC. Those most commonly used are cisplatin, carboplatin, and 5-FU, either as monotherapy or combination regimens.<sup>148,341,343-345,508-511,513,514</sup> Among EGFR inhibitors, cetuximab is most commonly used in this setting,<sup>347-349,352,508,512,515-517</sup> but there have also been prospective studies on gefitinib,<sup>351</sup> erlotinib,<sup>350</sup> panitumumab,<sup>518</sup> and lapatinib.<sup>346</sup> Results from retrospective studies and meta-analyses attempting to compare platinum-based cytotoxic therapy with cetuximab have yielded inconsistent results,<sup>348,511,519</sup> so it is not clear which of these agents is more effective at treating regional or distant metastatic cSCC. Several studies have reported on patients treated with combinations of EGFR inhibitors and cytotoxic agents,<sup>347,510,516</sup> but it is not yet clear whether the combination improves outcomes in patients with regional or distant metastatic cSCC.

### NCCN Recommendations for Treatment of Regional Disease

The preferred treatment for cSCC with lymph node involvement is excision of the primary tumor and regional lymph node dissection unless the patient is not a surgical candidate. Because surgery is the preferred treatment

approach, surgical candidacy should be assessed by a clinician with experience in performing regional lymph node dissections.

Patients treated with dissection of nodes in the trunk and extremities should consider adjuvant RT of the nodal bed, especially if multiple nodes are involved or if ECE is present. Dosage information can be found in the *Principles of Radiation Therapy for Squamous Cell Skin Cancer* section of the algorithm.

For patients with nodal metastasis to the head and neck, the extent of surgery should depend on the number, location, and size of effected nodes. Patients with a solitary positive lymph node should receive ipsilateral selective neck dissection. Comprehensive ipsilateral neck dissection is recommended for patients with a solitary positive node larger than 3 cm and those with multiple positive ipsilateral nodes. For patients with bilateral positive nodes, comprehensive bilateral neck dissection is appropriate. If parotid nodes are involved, the panel recommends superficial parotidectomy and ipsilateral neck dissection as indicated.

Truly radical neck dissection is no longer used and is not recommended. Because the definition of modified radical neck dissection varies across institutions, the NCCN Guidelines use the term “comprehensive neck dissection” to refer to all types of modified radical neck dissections, provided that they are more extensive procedures compared with selective neck dissections.

For patients with nodal metastasis to the head and neck, postoperative adjuvant treatment should depend on the pathologic findings after surgery—namely the extent resection, number of positive nodes, and presence or absence of ECE. Postoperative radiation is recommended in all cases, although observation is a reasonable alternative for patients with only one small ( $\leq 3$  cm) node and no ECE. Patients with ECE or incompletely excised nodes are at high risk of recurrence. They should



receive adjuvant RT and also consider concurrent systemic therapy depending on individual toxicity tolerance. Multidisciplinary consultation is recommended for these cases and should consider the systemic therapies used to treat head and neck squamous cell carcinomas as indicated in the NCCN Guidelines for Head and Neck Cancers.

Patients with inoperable nodal disease should be treated with radiation of the nodal bed and multidisciplinary consultation to consider concurrent systemic therapy. Systemic therapies recommended for use with radiation to treat head and neck squamous cell carcinomas should be considered.

Patients should be re-evaluated for surgical candidacy for lymph node dissection after radiation. CT with contrast may be indicated to evaluate the extent of residual disease.

## Recurrence and Metastasis

### Systemic Therapy for Distant Metastatic Disease

Cutaneous SCC with distant metastasis, while rare, is more common than metastatic BCC. A 10-year cohort study involving 985 patients with SCC found that patients with 1 primary cSCC have a 3.7% risk of lymph node metastasis and 2.1% risk of disease-specific death.<sup>17</sup> Risk of nodal disease is even lower in patients with only one primary cSCC.<sup>107</sup> Risk of distant metastatic disease is only 0.4%.<sup>17</sup> Unfortunately, evidence regarding systemic therapy for the condition is limited. There are no prospective phase III studies available. Whereas a number of small studies have reported responses to cytotoxic therapy in patients with local or regional cSCC (See *Systemic Therapy for Local High-Risk SCC* and *Systemic Therapy for Regional Disease*),<sup>334,342,343,509,511,513,520</sup> few of these studies included patients with distant metastatic cSCC.<sup>340,341,344,510</sup> Cisplatin either as a single agent or combined with 5-FU or vindesine has occasionally produced useful responses in patients with distant metastases from cSCC, but data supporting efficacy are limited.<sup>340,341,510</sup> In

the only phase II study of biochemotherapy with interferon alfa, cis-retinoic acid, and cisplatin, 35 patients were assessed for response, 11 of whom had distant metastases.<sup>344</sup> One of the 11 patients experienced a complete response. This lends some credence to a cisplatin-based regimen for distant metastatic disease.

The status of evidence supporting EGFR inhibitors for treatment of distant metastatic cSCC is similar to that for cytotoxic therapy. Multiple small studies, including some phase II trials, have shown responses to EGFR inhibitors in patients with locally advanced or regional disease,<sup>338,347,351,516</sup> but only a few have reported responses in patients with distant metastases, including 2 responses reported in phase II trials.<sup>346,352,512,515,518</sup> The low toxicity profile of cetuximab holds an advantage over the toxic cisplatin regimen.

Neoadjuvant systemic therapy in preparation for subsequent surgery and/or radiation has been used for locoregional cSCC that is very large and/or deeply invasive. For locoregional disease for which surgery or RT are unlikely to be curative, both cytotoxic and EGFR inhibitor systemic therapy (monotherapy or combination) have been successfully used to reduce tumor load, which in some cases enabled complete resection or complete response after RT.<sup>334,341,343,347,351,352,511,512,516</sup> The efficacy of this approach has not been demonstrated for patients with distant metastatic cSCC.

In addition to several trials testing new approaches to treating locally advanced unresectable or metastatic cSCC with cytotoxic or targeted agents,<sup>521-524</sup> checkpoint immunotherapies are also being tested in this setting.<sup>525-530</sup> Preliminary data from these studies and case reports have shown responses to anti-PD-1 (nivolumab, pembrolizumab, REGN2810) and anti-CTLA-4 (ipilimumab) agents.<sup>526,531-537</sup> FDA recently approved nivolumab and pembrolizumab monotherapy for the treatment of patients with recurrent or metastatic head and neck squamous cell cancer with



disease progression on or after platinum-containing chemotherapy.<sup>538,539</sup> However, neither the phase 3 trial supporting the nivolumab approval (Checkmate 041; NCT02105636) nor the phase 1b trial supporting the pembrolizumab approval (KEYNOTE-012; NCT01848834) included any patients with *cutaneous* SCC.<sup>540-542</sup>

### **NCCN Recommendations**

For the management of local tumor recurrence or new regional disease, the algorithm directs clinicians to follow the appropriate pathways for primary treatment. Complicated high-risk tumors, regional recurrence, or the development of distant metastases should be managed by a multidisciplinary tumor board.

The NCCN panel encourages participation in a clinical trial for patients with metastatic cSCC. Unfortunately such trials are scarce. Possible agents include cisplatin monotherapy, cisplatin plus 5-FU, EGFR inhibitors such as cetuximab, or immune checkpoint inhibitors. Currently there are insufficient published data to support recommending any specific immunotherapies for treatment of cSCC. If the patient is a solid organ transplant recipient taking immunosuppressive therapy, one should consider reducing the doses of immunosuppressive agents where appropriate or minimizing the doses of calcineurin inhibitors and/or antimetabolites in favor of mTOR inhibitors.<sup>543</sup> For symptomatic sites, palliative RT or surgery should be considered. Stereotactic body RT (SBRT) may be appropriate in select patients.

### **Follow-Up**

Two well-established points about patients with SCC underlie the follow-up schedules. One point is that 30% to 50% of these patients will develop another SCC within 5 years.<sup>102,105</sup> This represents at least a 10-fold increase in risk compared to the general population.<sup>104,105</sup> Patients with a prior SCC are also at increased risk of developing cutaneous melanoma

and BCC, and patients with multiple prior SCCs are at even higher risk.<sup>99,105</sup> Therefore, continued long-term surveillance of these patients is essential, as is patient education about the values of sun protection and regular self-examination of the skin. A second point is that 70% to 80% of all cutaneous SCC recurrences develop within 2 years of the initial therapy.<sup>17,48,107,122,127,544</sup> Therefore, close follow-up of these patients during this time period is critical.

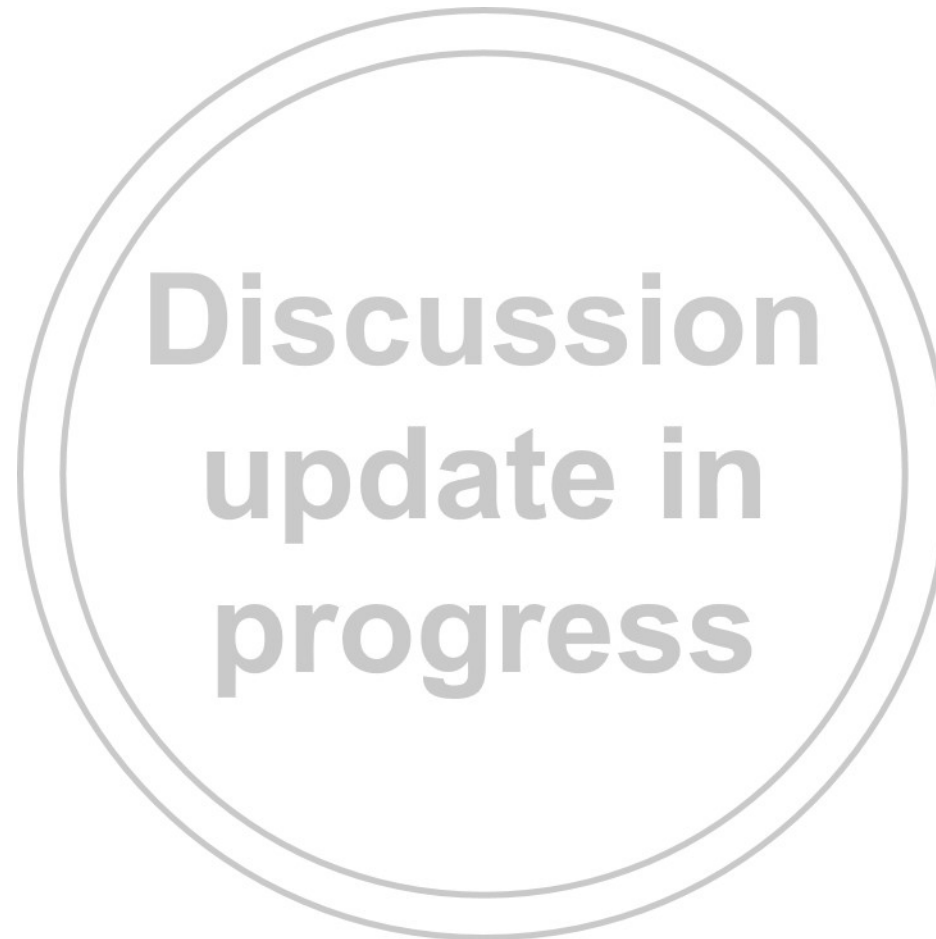### **NCCN Recommendations**

Patient education is a key component of follow-up for patients who have had cutaneous SCC. All patients should be made aware of the various resources that discuss skin cancer prevention. Patients should be educated in strict sun protection and taught how to perform a comprehensive self examination of skin. For those who had regional SCC, training in self examination of lymph nodes is also recommended.

Patients should also be monitored with regular physical exams including complete skin and regional lymph node examination. The frequency of follow-up should be adjusted based on risk. For local SCC, monitoring during the first 2 years is the most critical, and exams should occur at least every 3 to 12 months during this timeframe. If no further skin cancer develops in the first 2 years, then exams every 6 to 12 months for another 3 years, then annually for life is recommended. For regional SCC, a history and physical should be performed every 1 to 3 months for 1 year, then every 2 to 4 months for 1 year, every 4 to 6 months for another 3 years, and then every 6 to 12 months for life. For patients with regional disease, surveillance using CT with contrast may be warranted to screen for recurrence in the regional lymph node basin or distant metastatic disease. The target areas and frequency of these scans depends on the patient-specific clinical factors, and should ideally be determined by a multidisciplinary tumor board consultation.



In certain patients at high risk for multiple primary tumors, increased surveillance and consideration of prophylactic measures may be indicated.





## References

1. Stern RS. Prevalence of a history of skin cancer in 2007: results of an incidence-based model. *Arch Dermatol* 2010;146:279-282. Available at: <https://www.ncbi.nlm.nih.gov/pubmed/20231498>.
2. Rogers HW, Weinstock MA, Feldman SR, Coldiron BM. Incidence estimate of nonmelanoma skin cancer (keratinocyte carcinomas) in the U.S. population, 2012. *JAMA Dermatol* 2015;151:1081-1086. Available at: <http://www.ncbi.nlm.nih.gov/pubmed/25928283>.
3. Rubio-Casadevall J, Hernandez-Pujol AM, Ferreira-Santos MC, et al. Trends in incidence and survival analysis in non-melanoma skin cancer from 1994 to 2012 in Girona, Spain: A population-based study. *Cancer Epidemiol* 2016;45:6-10. Available at: <https://www.ncbi.nlm.nih.gov/pubmed/27639035>.
4. Sella T, Goren I, Shalev V, et al. Incidence trends of keratinocytic skin cancers and melanoma in Israel 2006-11. *Br J Dermatol* 2015;172:202-207. Available at: <https://www.ncbi.nlm.nih.gov/pubmed/24976239>.
5. Rudolph C, Schnoor M, Eisemann N, Katalinic A. Incidence trends of nonmelanoma skin cancer in Germany from 1998 to 2010. *J Dtsch Dermatol Ges* 2015;13:788-797. Available at: <http://www.ncbi.nlm.nih.gov/pubmed/26213814>.
6. Juzeniene A, Grigalavicius M, Baturaite Z, Moan J. Minimal and maximal incidence rates of skin cancer in Caucasians estimated by use of sigmoidal UV dose-incidence curves. *Int J Hyg Environ Health* 2014;217:839-844. Available at: <http://www.ncbi.nlm.nih.gov/pubmed/25023193>.
7. Hayes RC, Leonfellner S, Pilgrim W, et al. Incidence of nonmelanoma skin cancer in New Brunswick, Canada, 1992 to 2001. *J Cutan Med Surg* 2007;11:45-52. Available at: <http://www.ncbi.nlm.nih.gov/pubmed/17374314>.
8. Brewster DH, Bhatti LA, Inglis JH, et al. Recent trends in incidence of nonmelanoma skin cancers in the East of Scotland, 1992-2003. *Br J Dermatol* 2007;156:1295-1300. Available at: <http://www.ncbi.nlm.nih.gov/pubmed/17535229>.
9. Athas WF, Hunt WC, Key CR. Changes in nonmelanoma skin cancer incidence between 1977-1978 and 1998-1999 in Northcentral New Mexico. *Cancer Epidemiol Biomarkers Prev* 2003;12:1105-1108. Available at: <http://www.ncbi.nlm.nih.gov/pubmed/14578151>.
10. Christenson LJ, Borrowman TA, Vachon CM, et al. Incidence of basal cell and squamous cell carcinomas in a population younger than 40 years. *JAMA* 2005;294:681-690. Available at: <http://www.ncbi.nlm.nih.gov/pubmed/16091570>.
11. Goon PK, Greenberg DC, Igali L, Levell NJ. Squamous Cell Carcinoma of the Skin has More Than Doubled Over the Last Decade in the UK. *Acta Derm Venereol* 2016;96:820-821. Available at: <https://www.ncbi.nlm.nih.gov/pubmed/26631391>.
12. Robsahm TE, Helsing P, Veierod MB. Cutaneous squamous cell carcinoma in Norway 1963-2011: increasing incidence and stable mortality. *Cancer Med* 2015;4:472-480. Available at: <http://www.ncbi.nlm.nih.gov/pubmed/25620456>.
13. Perera E, Gnaneswaran N, Staines C, et al. Incidence and prevalence of non-melanoma skin cancer in Australia: A systematic review. *Australas J Dermatol* 2015;56:258-267. Available at: <http://www.ncbi.nlm.nih.gov/pubmed/25716064>.
14. Hemminki K, Zhang H, Czene K. Time trends and familial risks in squamous cell carcinoma of the skin. *Arch Dermatol* 2003;139:885-889. Available at: <https://www.ncbi.nlm.nih.gov/pubmed/12873883>.
15. Wassberg C, Thorn M, Johansson AM, et al. Increasing incidence rates of squamous cell carcinoma of the skin in Sweden. *Acta Derm Venereol* 2001;81:268-272. Available at: <http://www.ncbi.nlm.nih.gov/pubmed/11720174>.



16. Callens J, Van Eycken L, Henau K, Garmyn M. Epidemiology of basal and squamous cell carcinoma in Belgium: the need for a uniform and compulsory registration. *J Eur Acad Dermatol Venereol* 2016;30:1912-1918. Available at: <https://www.ncbi.nlm.nih.gov/pubmed/27256411>.
17. Schmults CD, Karia PS, Carter JB, et al. Factors predictive of recurrence and death from cutaneous squamous cell carcinoma: a 10-year, single-institution cohort study. *JAMA Dermatol* 2013;149:541-547. Available at: <http://www.ncbi.nlm.nih.gov/pubmed/23677079>.
18. Eisemann N, Jansen L, Castro FA, et al. Survival with nonmelanoma skin cancer in Germany. *Br J Dermatol* 2016;174:778-785. Available at: <https://www.ncbi.nlm.nih.gov/pubmed/26676514>.
19. Zanetti R, Rosso S, Martinez C, et al. Comparison of risk patterns in carcinoma and melanoma of the skin in men: a multi-centre case-case-control study. *Br J Cancer* 2006;94:743-751. Available at: <http://www.ncbi.nlm.nih.gov/pubmed/16495934>.
20. Gallagher RP, Hill GB, Bajdik CD, et al. Sunlight exposure, pigmentation factors, and risk of nonmelanocytic skin cancer. II. Squamous cell carcinoma. *Arch Dermatol* 1995;131:164-169. Available at: <http://www.ncbi.nlm.nih.gov/pubmed/7857112>.
21. Ramsay HM, Fryer AA, Hawley CM, et al. Factors associated with nonmelanoma skin cancer following renal transplantation in Queensland, Australia. *J Am Acad Dermatol* 2003;49:397-406. Available at: <http://www.ncbi.nlm.nih.gov/pubmed/12963901>.
22. English DR, Armstrong BK, Kricger A, et al. Case-control study of sun exposure and squamous cell carcinoma of the skin. *Int J Cancer* 1998;77:347-353. Available at: <http://www.ncbi.nlm.nih.gov/pubmed/9663594>.
23. English DR, Armstrong BK, Kricger A, et al. Demographic characteristics, pigmentary and cutaneous risk factors for squamous cell carcinoma of the skin: a case-control study. *Int J Cancer* 1998;76:628-634. Available at: <http://www.ncbi.nlm.nih.gov/pubmed/9610717>.
24. Wu S, Han J, Laden F, Qureshi AA. Long-term ultraviolet flux, other potential risk factors, and skin cancer risk: a cohort study. *Cancer Epidemiol Biomarkers Prev* 2014;23:1080-1089. Available at: <http://www.ncbi.nlm.nih.gov/pubmed/24876226>.
25. Xiang F, Lucas R, Hales S, Neale R. Incidence of nonmelanoma skin cancer in relation to ambient UV radiation in white populations, 1978-2012: empirical relationships. *JAMA Dermatol* 2014;150:1063-1071. Available at: <http://www.ncbi.nlm.nih.gov/pubmed/25103031>.
26. Green A, Battistutta D, Hart V, et al. Skin cancer in a subtropical Australian population: incidence and lack of association with occupation. The Nambour Study Group. *Am J Epidemiol* 1996;144:1034-1040. Available at: <https://www.ncbi.nlm.nih.gov/pubmed/8942434>.
27. Alfonso JH, Martinsen JI, Pukkala E, et al. Occupation and relative risk of cutaneous squamous cell carcinoma (cSCC): A 45-year follow-up study in 4 Nordic countries. *J Am Acad Dermatol* 2016;75:548-555. Available at: <https://www.ncbi.nlm.nih.gov/pubmed/27262759>.
28. Trakatelli M, Barkitzi K, Apap C, et al. Skin cancer risk in outdoor workers: a European multicenter case-control study. *J Eur Acad Dermatol Venereol* 2016;30 Suppl 3:5-11. Available at: <http://www.ncbi.nlm.nih.gov/pubmed/26995016>.
29. Xiong MY, Rizzo AE, Cohen TS, et al. Predictors of squamous cell carcinoma in high-risk patients in the VATTC trial. *J Invest Dermatol* 2013;133:1521-1532. Available at: <https://www.ncbi.nlm.nih.gov/pubmed/23348836>.
30. Suarez B, Lopez-Abente G, Martinez C, et al. Occupation and skin cancer: the results of the HELIOS-I multicenter case-control study. *BMC Public Health* 2007;7:180. Available at: <http://www.ncbi.nlm.nih.gov/pubmed/17655745>.
31. Wehner MR, Shive ML, Chren MM, et al. Indoor tanning and non-melanoma skin cancer: systematic review and meta-analysis. *BMJ* 2012;345:e5909. Available at: <https://www.ncbi.nlm.nih.gov/pubmed/23033409>.



32. Wehner MR, Chren MM, Nameth D, et al. International prevalence of indoor tanning: a systematic review and meta-analysis. *JAMA Dermatol* 2014;150:390-400. Available at: <http://www.ncbi.nlm.nih.gov/pubmed/24477278>.
33. Sitek A, Rosset I, Zadzińska E, et al. Skin color parameters and Fitzpatrick phototypes in estimating the risk of skin cancer: A case-control study in the Polish population. *J Am Acad Dermatol* 2016;74:716-723. Available at: <https://www.ncbi.nlm.nih.gov/pubmed/26777103>.
34. Box NF, Duffy DL, Irving RE, et al. Melanocortin-1 receptor genotype is a risk factor for basal and squamous cell carcinoma. *J Invest Dermatol* 2001;116:224-229. Available at: <http://www.ncbi.nlm.nih.gov/pubmed/11179997>.
35. Subramaniam P, Olsen CM, Thompson BS, et al. Anatomical Distributions of Basal Cell Carcinoma and Squamous Cell Carcinoma in a Population-Based Study in Queensland, Australia. *JAMA Dermatol* 2016;153:175-182. Available at: <https://www.ncbi.nlm.nih.gov/pubmed/27892984>.
36. Das KK, Chakarabarty A, Rahman A, Khandkar S. Incidences of malignancy in chronic burn scar ulcers: experience from Bangladesh. *Burns* 2015;41:1315-1321. Available at: <http://www.ncbi.nlm.nih.gov/pubmed/25716761>.
37. Senet P, Combemale P, Debure C, et al. Malignancy and chronic leg ulcers: the value of systematic wound biopsies: a prospective, multicenter, cross-sectional study. *Arch Dermatol* 2012;148:704-708. Available at: <https://www.ncbi.nlm.nih.gov/pubmed/22772403>.
38. Adigun IA, Buhari MO, Ayorinde RO. Malignant skin tumor in Blacks: experience in a teaching hospital. *West Afr J Med* 2006;25:276-278. Available at: <https://www.ncbi.nlm.nih.gov/pubmed/17402515>.
39. Khullar G, Saikia UN, De D, et al. Predisposing factors and histopathological variants of cutaneous squamous cell carcinoma: Experience from a North Indian teaching hospital. *Indian J Dermatol Venereol Leprol* 2016;82:273-278. Available at: <http://www.ncbi.nlm.nih.gov/pubmed/27088928>.
40. Combemale P, Bousquet M, Kanitakis J, et al. Malignant transformation of leg ulcers: a retrospective study of 85 cases. *J Eur Acad Dermatol Venereol* 2007;21:935-941. Available at: <https://www.ncbi.nlm.nih.gov/pubmed/17659003>.
41. Al-Zacko SM. Malignancy in chronic burn scar: a 20 year experience in Mosul-Iraq. *Burns* 2013;39:1488-1491. Available at: <https://www.ncbi.nlm.nih.gov/pubmed/23768719>.
42. Karasoy Yesilada A, Zeynep Sevim K, Ozgur Sucu D, et al. Marjolin ulcer: clinical experience with 34 patients over 15 years. *J Cutan Med Surg* 2013;17:404-409. Available at: <https://www.ncbi.nlm.nih.gov/pubmed/24138977>.
43. Onesti MG, Fino P, Fioramonti P, et al. Ten years of experience in chronic ulcers and malignant transformation. *Int Wound J* 2015;12:447-450. Available at: <https://www.ncbi.nlm.nih.gov/pubmed/23865503>.
44. Yakubu A, Mabogunje OA. Skin cancer in Zaria, Nigeria. *Trop Doct* 1995;25 Suppl 1:63-67. Available at: <http://www.ncbi.nlm.nih.gov/pubmed/7879275>.
45. Sadeh Fazeli M, Lebaschi AH, Hajirostam M, Keramati MR. Marjolin's ulcer: clinical and pathologic features of 83 cases and review of literature. *Med J Islam Repub Iran* 2013;27:215-224. Available at: <https://www.ncbi.nlm.nih.gov/pubmed/24926183>.
46. Nthumba PM. Marjolin's ulcers in sub-Saharan Africa. *World J Surg* 2010;34:2272-2277. Available at: <https://www.ncbi.nlm.nih.gov/pubmed/20645092>.



47. Snyder RJ, Stillman RM, Weiss SD. Epidermoid cancers that masquerade as venous ulcer disease. *Ostomy Wound Manage* 2003;49:63-66. Available at:

<https://www.ncbi.nlm.nih.gov/pubmed/12732742>.

48. Rowe DE, Carroll RJ, Day CL, Jr. Prognostic factors for local recurrence, metastasis, and survival rates in squamous cell carcinoma of the skin, ear, and lip. Implications for treatment modality selection. *J Am Acad Dermatol* 1992;26:976-990. Available at:

<http://www.ncbi.nlm.nih.gov/pubmed/1607418>.

49. Eroglu A, Berberoglu U, Berreroğlu S. Risk factors related to locoregional recurrence in squamous cell carcinoma of the skin. *J Surg Oncol* 1996;61:124-130. Available at:

<http://www.ncbi.nlm.nih.gov/pubmed/8606543>.

50. Mullen JT, Feng L, Xing Y, et al. Invasive squamous cell carcinoma of the skin: defining a high-risk group. *Ann Surg Oncol* 2006;13:902-909.

Available at: <http://www.ncbi.nlm.nih.gov/pubmed/16788750>.

51. de Lima Vazquez V, Sachetto T, Perpetuo NM, Carvalho AL. Prognostic factors for lymph node metastasis from advanced squamous cell carcinoma of the skin of the trunk and extremities. *World J Surg Oncol* 2008;6:73. Available at: <https://www.ncbi.nlm.nih.gov/pubmed/18601735>.

52. Edwards MJ, Hirsch RM, Broadwater JR, et al. Squamous cell carcinoma arising in previously burned or irradiated skin. *Arch Surg* 1989;124:115-117. Available at:

<http://www.ncbi.nlm.nih.gov/pubmed/2910238>.

53. Asuquo ME, Ikpeme IA, Basseyy EE, Ebughe G. Squamous cell carcinoma in South-Eastern equatorial rain forest in calabar, Nigeria. *Eplasty* 2009;9:483-488. Available at:

<https://www.ncbi.nlm.nih.gov/pubmed/20011213>.

54. Natafji N, Tidman MJ. Improving detection of non-melanoma skin cancer Non-melanoma skin cancer. *Practitioner* 2015;259:23-27, 23.

Available at: <https://www.ncbi.nlm.nih.gov/pubmed/26514057>.

55. Choi SH, Kim KH, Song KH. Clinical Features of Cutaneous Premalignant Lesions in Busan City and the Eastern Gyeongnam Province, Korea: A Retrospective Review of 1,292 Cases over 19 Years (1995~2013). *Ann Dermatol* 2016;28:172-178. Available at:

<http://www.ncbi.nlm.nih.gov/pubmed/27081263>.

56. Dika E, Fanti PA, Misciali C, et al. Risk of skin cancer development in 672 patients affected by actinic keratosis. *G Ital Dermatol Venereol* 2016;151:628-633. Available at:

<https://www.ncbi.nlm.nih.gov/pubmed/26381460>.

57. van Rijsingen M, Seubring I, Maessen-Visch B, et al. Insight into the number of pre-malignancies and malignancies of the skin in a hospital population in the Netherlands. *Eur J Dermatol* 2015;25:261-265. Available at:

<http://www.ncbi.nlm.nih.gov/pubmed/25786488>.

58. Mittelbronn MA, Mullins DL, Ramos-Caro FA, Flowers FP. Frequency of pre-existing actinic keratosis in cutaneous squamous cell carcinoma. *Int J Dermatol* 1998;37:677-681. Available at:

<https://www.ncbi.nlm.nih.gov/pubmed/9762818>.

59. Dinehart SM, Nelson-Adesokan P, Cockerell C, et al. Metastatic cutaneous squamous cell carcinoma derived from actinic keratosis. *Cancer* 1997;79:920-923. Available at:

<https://www.ncbi.nlm.nih.gov/pubmed/9041154>.

60. Glogau RG. The risk of progression to invasive disease. *J Am Acad Dermatol* 2000;42:23-24. Available at:

<https://www.ncbi.nlm.nih.gov/pubmed/10607353>.

61. Marks R, Rennie G, Selwood TS. Malignant transformation of solar keratoses to squamous cell carcinoma. *Lancet* 1988;1:795-797. Available at:

<https://www.ncbi.nlm.nih.gov/pubmed/2895318>.

62. Criscione VD, Weinstock MA, Naylor MF, et al. Actinic keratoses: Natural history and risk of malignant transformation in the Veterans Affairs Topical Tretinoin Chemoprevention Trial. *Cancer* 2009;115:2523-2530.

Available at: <https://www.ncbi.nlm.nih.gov/pubmed/19382202>.



63. Marks R, Foley P, Goodman G, et al. Spontaneous remission of solar keratoses: the case for conservative management. *Br J Dermatol* 1986;115:649-655. Available at: <https://www.ncbi.nlm.nih.gov/pubmed/3801305>.
64. Eimpunth S, Goldenberg A, Hamman MS, et al. Squamous Cell Carcinoma In Situ Upstaged to Invasive Squamous Cell Carcinoma: A 5-Year, Single Institution Retrospective Review. *Dermatol Surg* 2017;43:698-703. Available at: <https://www.ncbi.nlm.nih.gov/pubmed/28060173>.
65. Kromberg JG, Castle D, Zwane EM, Jenkins T. Albinism and skin cancer in Southern Africa. *Clin Genet* 1989;36:43-52. Available at: <http://www.ncbi.nlm.nih.gov/pubmed/2766562>.
66. Adegbidi H, Yedomon H, Atadokpede F, et al. Skin cancers at the National University Hospital of Cotonou from 1985 to 2004. *Int J Dermatol* 2007;46 Suppl 1:26-29. Available at: <http://www.ncbi.nlm.nih.gov/pubmed/17919202>.
67. Kiprono SK, Chaula BM, Beltraminelli H. Histological review of skin cancers in African Albinos: a 10-year retrospective review. *BMC Cancer* 2014;14:157. Available at: <https://www.ncbi.nlm.nih.gov/pubmed/24597988>.
68. Luande J, Henschke CI, Mohammed N. The Tanzanian human albino skin. *Natural history. Cancer* 1985;55:1823-1828. Available at: <http://www.ncbi.nlm.nih.gov/pubmed/3978567>.
69. Mabula JB, Chalya PL, McHembe MD, et al. Skin cancers among Albinos at a University teaching hospital in Northwestern Tanzania: a retrospective review of 64 cases. *BMC Dermatol* 2012;12:5. Available at: <https://www.ncbi.nlm.nih.gov/pubmed/22681652>.
70. Yakubu A, Mabogunje OA. Skin cancer in African albinos. *Acta Oncol* 1993;32:621-622. Available at: <http://www.ncbi.nlm.nih.gov/pubmed/8260178>.
71. Opara KO, Jiburum BC. Skin cancers in albinos in a teaching Hospital in eastern Nigeria - presentation and challenges of care. *World J Surg Oncol* 2010;8:73. Available at: <https://www.ncbi.nlm.nih.gov/pubmed/20738853>.
72. Asuquo ME, Ebughe G. Major dermatological malignancies encountered in the University of Calabar Teaching Hospital, Calabar, southern Nigeria. *Int J Dermatol* 2012;51 Suppl 1:32-40. Available at: <https://www.ncbi.nlm.nih.gov/pubmed/23210953>.
73. Halkud R, Shenoy AM, Naik SM, et al. Xeroderma pigmentosum: clinicopathological review of the multiple oculocutaneous malignancies and complications. *Indian J Surg Oncol* 2014;5:120-124. Available at: <http://www.ncbi.nlm.nih.gov/pubmed/25114464>.
74. Kraemer KH, Lee MM, Scotto J. Xeroderma pigmentosum. Cutaneous, ocular, and neurologic abnormalities in 830 published cases. *Arch Dermatol* 1987;123:241-250. Available at: <http://www.ncbi.nlm.nih.gov/pubmed/3545087>.
75. Bradford PT, Goldstein AM, Tamura D, et al. Cancer and neurologic degeneration in xeroderma pigmentosum: long term follow-up characterises the role of DNA repair. *J Med Genet* 2011;48:168-176. Available at: <http://www.ncbi.nlm.nih.gov/pubmed/21097776>.
76. Kraemer KH, Lee MM, Andrews AD, Lambert WC. The role of sunlight and DNA repair in melanoma and nonmelanoma skin cancer. The xeroderma pigmentosum paradigm. *Arch Dermatol* 1994;130:1018-1021. Available at: <http://www.ncbi.nlm.nih.gov/pubmed/8053698>.
77. Kraemer KH, Lee MM, Scotto J. DNA repair protects against cutaneous and internal neoplasia: evidence from xeroderma pigmentosum. *Carcinogenesis* 1984;5:511-514. Available at: <http://www.ncbi.nlm.nih.gov/pubmed/6705149>.
78. Thielmann HW, Popanda O, Edler L, Jung EG. Clinical symptoms and DNA repair characteristics of xeroderma pigmentosum patients from Germany. *Cancer Res* 1991;51:3456-3470. Available at: <http://www.ncbi.nlm.nih.gov/pubmed/2054785>.



79. Miller KL, Karagas MR, Kraft P, et al. XPA, haplotypes, and risk of basal and squamous cell carcinoma. *Carcinogenesis* 2006;27:1670-1675. Available at: <http://www.ncbi.nlm.nih.gov/pubmed/16513681>.

80. Miranda MB, Lauseker M, Kraus MP, et al. Secondary malignancies in chronic myeloid leukemia patients after imatinib-based treatment: long-term observation in CML Study IV. *Leukemia* 2016;30:1255-1262. Available at: <https://www.ncbi.nlm.nih.gov/pubmed/26859076>.

81. Kolaitis NA, Duffy E, Zhang A, et al. Voriconazole increases the risk for cutaneous squamous cell carcinoma after lung transplantation. *Transpl Int* 2017;30:41-48. Available at: <https://www.ncbi.nlm.nih.gov/pubmed/27678492>.

82. Jensen AO, Svaerke C, Farkas D, et al. Skin cancer risk among solid organ recipients: a nationwide cohort study in Denmark. *Acta Derm Venereol* 2010;90:474-479. Available at: <http://www.ncbi.nlm.nih.gov/pubmed/20814621>.

83. Jensen P, Hansen S, Moller B, et al. Skin cancer in kidney and heart transplant recipients and different long-term immunosuppressive therapy regimens. *J Am Acad Dermatol* 1999;40:177-186. Available at: <http://www.ncbi.nlm.nih.gov/pubmed/10025742>.

84. Shang W, Ning Y, Xu X, et al. Incidence of Cancer in ANCA-Associated Vasculitis: A Meta-Analysis of Observational Studies. *PLoS One* 2015;10:e0126016. Available at: <https://www.ncbi.nlm.nih.gov/pubmed/25973882>.

85. Shah BK, Khanal A. Second Primary Malignancies in Mantle Cell Lymphoma: A US Population-based Study. *Anticancer Res* 2015;35:3437-3440. Available at: <https://www.ncbi.nlm.nih.gov/pubmed/26026107>.

86. Brewer JD, Shanafelt TD, Khezri F, et al. Increased incidence and recurrence rates of nonmelanoma skin cancer in patients with non-Hodgkin lymphoma: a Rochester Epidemiology Project population-based study in Minnesota. *J Am Acad Dermatol* 2015;72:302-309. Available at: <https://www.ncbi.nlm.nih.gov/pubmed/25479909>.

87. Gerber SR, Seifert B, Inci I, et al. Exposure to moxifloxacin and cytomegalovirus replication is associated with skin squamous cell carcinoma development in lung transplant recipients. *J Eur Acad Dermatol Venereol* 2015;29:2451-2457. Available at: <http://www.ncbi.nlm.nih.gov/pubmed/26403508>.

88. Burger B, Sporri I, Stegmann DA, et al. Risk of Cutaneous Squamous Cell Carcinoma Development in Renal Transplant Recipients Is Independent of TMC/EVER Alterations. *Dermatology* 2015;231:245-252. Available at: <https://www.ncbi.nlm.nih.gov/pubmed/26227733>.

89. Asgari MM, Arron ST, Warton EM, et al. Sirolimus use and risk of cutaneous squamous cell carcinoma (SCC) in solid organ transplant recipients (SOTRs). *J Am Acad Dermatol* 2015;73:444-450. Available at: <https://www.ncbi.nlm.nih.gov/pubmed/26138646>.

90. Silverberg MJ, Leyden W, Warton EM, et al. HIV infection status, immunodeficiency, and the incidence of non-melanoma skin cancer. *J Natl Cancer Inst* 2013;105:350-360. Available at: <http://www.ncbi.nlm.nih.gov/pubmed/23291375>.

91. Patel RV, Clark LN, Lebwohl M, Weinberg JM. Treatments for psoriasis and the risk of malignancy. *J Am Acad Dermatol* 2009;60:1001-1017. Available at: <http://www.ncbi.nlm.nih.gov/pubmed/19344980>.

92. Zilinska Z, Sersenova M, Chrastina M, et al. Occurrence of malignancies after kidney transplantation in adults: Slovak multicenter experience. *Neoplasma* 2017;64:311-317. Available at: <https://www.ncbi.nlm.nih.gov/pubmed/28052685>.

93. Garritsen FM, van der Schaft J, van den Reek JM, et al. Risk of Non-melanoma Skin Cancer in Patients with Atopic Dermatitis Treated with Oral Immunosuppressive Drugs. *Acta Derm Venereol* 2017;97:724-730. Available at: <https://www.ncbi.nlm.nih.gov/pubmed/28218345>.

94. van den Heuvel TR, Wintjens DS, Jeurig SF, et al. Inflammatory bowel disease, cancer and medication: Cancer risk in the Dutch population-based IBDSL cohort. *Int J Cancer* 2016;139:1270-1280. Available at: <https://www.ncbi.nlm.nih.gov/pubmed/27170593>.



95. Diffey BL, Norval M, Albers PN, Wright CY. The influence of HIV infection on the age dependence of squamous cell carcinoma of the skin in South Africa. *S Afr Med J* 2017;107:127-129. Available at: <https://www.ncbi.nlm.nih.gov/pubmed/28220738>.

96. Hock BD, McIntosh ND, McKenzie JL, et al. Incidence of cutaneous squamous cell carcinoma in a New Zealand population of chronic lymphocytic leukaemia patients. *Intern Med J* 2016;46:1414-1421. Available at: <https://www.ncbi.nlm.nih.gov/pubmed/27664975>.

97. Gupta AK, Cardella CJ, Haberman HF. Cutaneous malignant neoplasms in patients with renal transplants. *Arch Dermatol* 1986;122:1288-1293. Available at: <http://www.ncbi.nlm.nih.gov/pubmed/3535683>.

98. Chen J, Ruczinski I, Jorgensen TJ, et al. Nonmelanoma skin cancer and risk for subsequent malignancy. *J Natl Cancer Inst* 2008;100:1215-1222. Available at: <http://www.ncbi.nlm.nih.gov/pubmed/18728282>.

99. Banan P, Marvi SK, McMeniman E, De'Ambrosis B. An Australian cohort of 210 patients with multiple invasive squamous cell carcinomas: risk factors and associated increased risk of melanoma and internal malignancies. *Australas J Dermatol* 2016;57:29-32. Available at: <https://www.ncbi.nlm.nih.gov/pubmed/25970074>.

100. Raasch BA, Buettner PG. Multiple nonmelanoma skin cancer in an exposed Australian population. *Int J Dermatol* 2002;41:652-658. Available at: <https://www.ncbi.nlm.nih.gov/pubmed/12390187>.

101. English DR, Krickler A, Heenan PJ, et al. Incidence of non-melanocytic skin cancer in Geraldton, Western Australia. *Int J Cancer* 1997;73:629-633. Available at: <http://www.ncbi.nlm.nih.gov/pubmed/9398037>.

102. Karagas MR, Stukel TA, Greenberg ER, et al. Risk of subsequent basal cell carcinoma and squamous cell carcinoma of the skin among patients with prior skin cancer. Skin Cancer Prevention Study Group. *JAMA* 1992;267:3305-3310. Available at: <http://www.ncbi.nlm.nih.gov/pubmed/1597912>.

103. Karagas MR, Greenberg ER, Spencer SK, et al. Increase in incidence rates of basal cell and squamous cell skin cancer in New Hampshire, USA. New Hampshire Skin Cancer Study Group. *Int J Cancer* 1999;81:555-559. Available at: <http://www.ncbi.nlm.nih.gov/pubmed/10225444>.

104. Marcil I, Stern RS. Risk of developing a subsequent nonmelanoma skin cancer in patients with a history of nonmelanoma skin cancer: a critical review of the literature and meta-analysis. *Arch Dermatol* 2000;136:1524-1530. Available at: <http://www.ncbi.nlm.nih.gov/pubmed/11115165>.

105. Flohil SC, van der Leest RJ, Arends LR, et al. Risk of subsequent cutaneous malignancy in patients with prior keratinocyte carcinoma: a systematic review and meta-analysis. *Eur J Cancer* 2013;49:2365-2375. Available at: <http://www.ncbi.nlm.nih.gov/pubmed/23608733>.

106. Wehner MR, Linos E, Parvataneni R, et al. Timing of subsequent new tumors in patients who present with Basal cell carcinoma or cutaneous squamous cell carcinoma. *JAMA Dermatol* 2015;151:382-388. Available at: <http://www.ncbi.nlm.nih.gov/pubmed/25588079>.

107. Levine DE, Karia PS, Schmults CD. Outcomes of Patients With Multiple Cutaneous Squamous Cell Carcinomas: A 10-Year Single-Institution Cohort Study. *JAMA Dermatol* 2015;151:1220-1225. Available at: <http://www.ncbi.nlm.nih.gov/pubmed/26177278>.

108. Maloney ME, Miller SJ. Aggressive vs nonaggressive subtypes (basal cell carcinoma). In: Miller SJ, Maloney ME, eds. *Cutaneous Oncology Pathophysiology, diagnosis, and management*. Malden, MA: Blackwell Science; 1998:609-613.

109. Salasche SJ. Features associated with recurrence (squamous cell carcinoma). In: Miller SJ, Maloney ME, eds. *Cutaneous Oncology Pathophysiology, diagnosis, and management*. Malden, MA: Blackwell Science; 1998:494-499.



110. Akay BN, Saral S, Heper AO, et al. Basosquamous carcinoma: Dermoscopic clues to diagnosis. *J Dermatol* 2017;44:127-134. Available at: <https://www.ncbi.nlm.nih.gov/pubmed/27570202>.

111. Wermker K, Roknic N, Goessling K, et al. Basosquamous carcinoma of the head and neck: clinical and histologic characteristics and their impact on disease progression. *Neoplasia* 2015;17:301-305. Available at: <https://www.ncbi.nlm.nih.gov/pubmed/25810014>.

112. Tan CZ, Rieger KE, Sarin KY. Basosquamous Carcinoma: Controversy, Advances, and Future Directions. *Dermatol Surg* 2017;43:23-31. Available at: <https://www.ncbi.nlm.nih.gov/pubmed/27340741>.

113. de Faria J. Basal cell carcinoma of the skin with areas of squamous cell carcinoma: a basosquamous cell carcinoma? *J Clin Pathol* 1985;38:1273-1277. Available at: <https://www.ncbi.nlm.nih.gov/pubmed/4066987>.

114. Marrazzo G, Thorpe R, Condie D, et al. Clinical and Pathologic Factors Predictive of Positive Radiologic Findings in High-Risk Cutaneous Squamous Cell Carcinoma. *Dermatol Surg* 2015;41:1405-1410. Available at: <http://www.ncbi.nlm.nih.gov/pubmed/26517320>.

115. Ruiz ES, Karia PS, Morgan FC, Schmults CD. The positive impact of radiologic imaging on high-stage cutaneous squamous cell carcinoma management. *J Am Acad Dermatol* 2017;76:217-225. Available at: <https://www.ncbi.nlm.nih.gov/pubmed/27707594>.

116. Gandhi MR, Panizza B, Kennedy D. Detecting and defining the anatomic extent of large nerve perineural spread of malignancy: comparing "targeted" MRI with the histologic findings following surgery. *Head Neck* 2011;33:469-475. Available at: <http://www.ncbi.nlm.nih.gov/pubmed/20645285>.

117. Williams LS, Mancuso AA, Mendenhall WM. Perineural spread of cutaneous squamous and basal cell carcinoma: CT and MR detection and its impact on patient management and prognosis. *Int J Radiat Oncol Biol Phys* 2001;49:1061-1069. Available at: <http://www.ncbi.nlm.nih.gov/pubmed/11240248>.

118. Nemzek WR, Hecht S, Gandour-Edwards R, et al. Perineural spread of head and neck tumors: how accurate is MR imaging? *AJNR Am J Neuroradiol* 1998;19:701-706. Available at: <http://www.ncbi.nlm.nih.gov/pubmed/9576658>.

119. Cutaneous squamous cell carcinoma and other cutaneous carcinomas. In: Edge SB, Carducci M, Byrd DR, eds. *AJCC Cancer Staging Manual* (ed 7). New York: Springer-Verlag New York, LLC; 2009.

120. Farasat S, Yu SS, Neel VA, et al. A new American Joint Committee on Cancer staging system for cutaneous squamous cell carcinoma: Creation and rationale for inclusion of tumor (T) characteristics. *J Am Acad Dermatol* 2011;64:1051-1059. Available at: <http://www.ncbi.nlm.nih.gov/pubmed/21255868>.

121. Jambusaria-Pahlajani A, Kanetsky PA, Karia PS, et al. Evaluation of AJCC tumor staging for cutaneous squamous cell carcinoma and a proposed alternative tumor staging system. *JAMA Dermatol* 2013;149:402-410. Available at: <http://www.ncbi.nlm.nih.gov/pubmed/23325457>.

122. Karia PS, Jambusaria-Pahlajani A, Harrington DP, et al. Evaluation of American Joint Committee on Cancer, International Union Against Cancer, and Brigham and Women's Hospital tumor staging for cutaneous squamous cell carcinoma. *J Clin Oncol* 2014;32:327-334. Available at: <https://www.ncbi.nlm.nih.gov/pubmed/24366933>.

123. Schmitt AR, Brewer JD, Bordeaux JS, Baum CL. Staging for cutaneous squamous cell carcinoma as a predictor of sentinel lymph node biopsy results: meta-analysis of American Joint Committee on Cancer criteria and a proposed alternative system. *JAMA Dermatol* 2014;150:19-24. Available at: <http://www.ncbi.nlm.nih.gov/pubmed/24226651>.



124. Gonzalez JL, Cunningham K, Silverman R, et al. Comparison of the American Joint Committee on Cancer Seventh Edition and Brigham and Women's Hospital Cutaneous Squamous Cell Carcinoma Tumor Staging in Immunosuppressed Patients. *Dermatol Surg* 2017;43:784-791. Available at: <https://www.ncbi.nlm.nih.gov/pubmed/28079640>.

125. Thompson AK, Kelley BF, Prokop LJ, et al. Risk Factors for Cutaneous Squamous Cell Carcinoma Recurrence, Metastasis, and Disease-Specific Death: A Systematic Review and Meta-analysis. *JAMA Dermatol* 2016;152:419-428. Available at: <http://www.ncbi.nlm.nih.gov/pubmed/26762219>.

126. Brantsch KD, Meisner C, Schonfisch B, et al. Analysis of risk factors determining prognosis of cutaneous squamous-cell carcinoma: a prospective study. *Lancet Oncol* 2008;9:713-720. Available at: <http://www.ncbi.nlm.nih.gov/pubmed/18617440>.

127. Roozeboom MH, Lohman BG, Westers-Attema A, et al. Clinical and histological prognostic factors for local recurrence and metastasis of cutaneous squamous cell carcinoma: analysis of a defined population. *Acta Derm Venereol* 2013;93:417-421. Available at: <https://www.ncbi.nlm.nih.gov/pubmed/23138613>.

128. Carter JB, Johnson MM, Chua TL, et al. Outcomes of primary cutaneous squamous cell carcinoma with perineural invasion: an 11-year cohort study. *JAMA Dermatol* 2013;149:35-41. Available at: <http://www.ncbi.nlm.nih.gov/pubmed/23324754>.

129. Amin MB, Edge S, Greene F, et al., eds. *AJCC Cancer Staging Manual* (ed 8th). New York: Springer International Publishing; 2017.

130. Haas AF. Features associated with metastasis (squamous cell carcinoma). In: Miller SJ, Maloney ME, eds. *Cutaneous Oncology Pathophysiology, diagnosis, and management*. Malden, MA: Blackwell Science; 1998:500-505.

131. Brougham ND, Dennett ER, Cameron R, Tan ST. The incidence of metastasis from cutaneous squamous cell carcinoma and the impact of its risk factors. *J Surg Oncol* 2012;106:811-815. Available at: <https://www.ncbi.nlm.nih.gov/pubmed/22592943>.

132. Harris BN, Bayoumi A, Rao S, et al. Factors Associated with Recurrence and Regional Adenopathy for Head and Neck Cutaneous Squamous Cell Carcinoma. *Otolaryngol Head Neck Surg* 2017;156:863-869. Available at: <https://www.ncbi.nlm.nih.gov/pubmed/28322123>.

133. Swanson NA. Mohs surgery. Technique, indications, applications, and the future. *Arch Dermatol* 1983;119:761-773. Available at: <http://www.ncbi.nlm.nih.gov/pubmed/6351758>.

134. Swanson NA, Johnson TM. Management of basal and squamous cell carcinoma. In: Cummings C, ed. *Otolaryngology Head and Neck Surgery*. New York: Mosby Yearbook; 1998:486-501.

135. Silverman MK, Kopf AW, Grin CM, et al. Recurrence rates of treated basal cell carcinomas. Part 1: Overview. *J Dermatol Surg Oncol* 1991;17:713-718. Available at: <http://www.ncbi.nlm.nih.gov/pubmed/1890243>.

136. Silverman MK, Kopf AW, Grin CM, et al. Recurrence rates of treated basal cell carcinomas. Part 2: Curettage-electrodesiccation. *J Dermatol Surg Oncol* 1991;17:720-726. Available at: <http://www.ncbi.nlm.nih.gov/pubmed/1820764>.

137. Connolly AH, Baker DR, Coldiron BM, et al. AAD/ACMS/ASDSA/ASMS 2012 appropriate use criteria for mohs micrographic surgery: a report of the American Academy of Dermatology, American College of Mohs Surgery, American Society for Dermatologic Surgery Association, and the American Society for Mohs Surgery. *Dermatol Surg* 2012;38:1582-1603. Available at: <http://www.ncbi.nlm.nih.gov/pubmed/22958088>.

138. Clayman GL, Lee JJ, Holsinger FC, et al. Mortality risk from squamous cell skin cancer. *J Clin Oncol* 2005;23:759-765. Available at: <http://www.ncbi.nlm.nih.gov/pubmed/15681519>.



139. Quaedvlieg PJ, Creytens DH, Epping GG, et al. Histopathological characteristics of metastasizing squamous cell carcinoma of the skin and lips. *Histopathology* 2006;49:256-264. Available at: <https://www.ncbi.nlm.nih.gov/pubmed/16918972>.

140. Haisma MS, Plaat BE, Bijl HP, et al. Multivariate analysis of potential risk factors for lymph node metastasis in patients with cutaneous squamous cell carcinoma of the head and neck. *J Am Acad Dermatol* 2016;75:722-730. Available at: <https://www.ncbi.nlm.nih.gov/pubmed/27473455>.

141. Cherpelis BS, Marcusen C, Lang PG. Prognostic factors for metastasis in squamous cell carcinoma of the skin. *Dermatol Surg* 2002;28:268-273. Available at: <http://www.ncbi.nlm.nih.gov/pubmed/11896781>.

142. Maciburko SJ, Townley WA, Hollowood K, Giele HP. Skin cancers of the hand: a series of 541 malignancies. *Plast Reconstr Surg* 2012;129:1329-1336. Available at: <https://www.ncbi.nlm.nih.gov/pubmed/22327895>.

143. Wermker K, Kluwig J, Schipmann S, et al. Prediction score for lymph node metastasis from cutaneous squamous cell carcinoma of the external ear. *Eur J Surg Oncol* 2015;41:128-135. Available at: <https://www.ncbi.nlm.nih.gov/pubmed/25182221>.

144. Moore BA, Weber RS, Prieto V, et al. Lymph node metastases from cutaneous squamous cell carcinoma of the head and neck. *Laryngoscope* 2005;115:1561-1567. Available at: <http://www.ncbi.nlm.nih.gov/pubmed/16148695>.

145. Palme CE, O'Brien CJ, Veness MJ, et al. Extent of parotid disease influences outcome in patients with metastatic cutaneous squamous cell carcinoma. *Arch Otolaryngol Head Neck Surg* 2003;129:750-753. Available at: <http://www.ncbi.nlm.nih.gov/pubmed/12874077>.

146. Oddone N, Morgan GJ, Palme CE, et al. Metastatic cutaneous squamous cell carcinoma of the head and neck: the Immunosuppression, Treatment, Extranodal spread, and Margin status (ITEM) prognostic score to predict outcome and the need to improve survival. *Cancer* 2009;115:1883-1891. Available at: <https://www.ncbi.nlm.nih.gov/pubmed/19224549>.

147. Wang JT, Palme CE, Wang AY, et al. In patients with metastatic cutaneous head and neck squamous cell carcinoma to cervical lymph nodes, the extent of neck dissection does not influence outcome. *J Laryngol Otol* 2013;127 Suppl 1:S2-7. Available at: <https://www.ncbi.nlm.nih.gov/pubmed/23046820>.

148. McDowell LJ, Tan TJ, Bressel M, et al. Outcomes of cutaneous squamous cell carcinoma of the head and neck with parotid metastases. *J Med Imaging Radiat Oncol* 2016;60:668-676. Available at: <https://www.ncbi.nlm.nih.gov/pubmed/27324298>.

149. Schmidt C, Martin JM, Khoo E, et al. Outcomes of nodal metastatic cutaneous squamous cell carcinoma of the head and neck treated in a regional center. *Head Neck* 2015;37:1808-1815. Available at: <https://www.ncbi.nlm.nih.gov/pubmed/24995842>.

150. Southwell KE, Chaplin JM, Eisenberg RL, et al. Effect of immunocompromise on metastatic cutaneous squamous cell carcinoma in the parotid and neck. *Head Neck* 2006;28:244-248. Available at: <https://www.ncbi.nlm.nih.gov/pubmed/16395715>.

151. Ch'ng S, Maitra A, Allison RS, et al. Parotid and cervical nodal status predict prognosis for patients with head and neck metastatic cutaneous squamous cell carcinoma. *J Surg Oncol* 2008;98:101-105. Available at: <http://www.ncbi.nlm.nih.gov/pubmed/18523982>.

152. Shao A, Wong DK, Mclvor NP, et al. Parotid metastatic disease from cutaneous squamous cell carcinoma: prognostic role of facial nerve sacrifice, lateral temporal bone resection, immune status and P-stage. *Head Neck* 2014;36:545-550. Available at: <https://www.ncbi.nlm.nih.gov/pubmed/23780509>.



153. Manyam BV, Gastman B, Zhang AY, et al. Inferior outcomes in immunosuppressed patients with high-risk cutaneous squamous cell carcinoma of the head and neck treated with surgery and radiation therapy. *J Am Acad Dermatol* 2015;73:221-227. Available at: <https://www.ncbi.nlm.nih.gov/pubmed/26028524>.

154. Lott DG, Manz R, Koch C, Lorenz RR. Aggressive behavior of nonmelanotic skin cancers in solid organ transplant recipients. *Transplantation* 2010;90:683-687. Available at: <http://www.ncbi.nlm.nih.gov/pubmed/20808266>.

155. Manyam BV, Garsa AA, Chin RI, et al. A multi-institutional comparison of outcomes of immunosuppressed and immunocompetent patients treated with surgery and radiation therapy for cutaneous squamous cell carcinoma of the head and neck. *Cancer* 2017;123:2054-2060. Available at: <https://www.ncbi.nlm.nih.gov/pubmed/28171708>.

156. Harwood CA, Proby CM, McGregor JM, et al. Clinicopathologic features of skin cancer in organ transplant recipients: a retrospective case-control series. *J Am Acad Dermatol* 2006;54:290-300. Available at: <http://www.ncbi.nlm.nih.gov/pubmed/16443060>.

157. Rabinovics N, Mizrahi A, Hadar T, et al. Cancer of the head and neck region in solid organ transplant recipients. *Head Neck* 2014;36:181-186. Available at: <http://www.ncbi.nlm.nih.gov/pubmed/23554129>.

158. Goldenberg A, Ortiz A, Kim SS, Jiang SB. Squamous cell carcinoma with aggressive subclinical extension: 5-year retrospective review of diagnostic predictors. *J Am Acad Dermatol* 2015;73:120-126. Available at: <http://www.ncbi.nlm.nih.gov/pubmed/25840729>.

159. Martin H, Strong E, Spiro RH. Radiation-induced skin cancer of the head and neck. *Cancer* 1970;25:61-71. Available at: <http://www.ncbi.nlm.nih.gov/pubmed/4312028>.

160. Gul U, Kilic A. Squamous cell carcinoma developing on burn scar. *Ann Plast Surg* 2006;56:406-408. Available at: <http://www.ncbi.nlm.nih.gov/pubmed/16557073>.

161. Kowal-Vern A, Criswell BK. Burn scar neoplasms: a literature review and statistical analysis. *Burns* 2005;31:403-413. Available at: <http://www.ncbi.nlm.nih.gov/pubmed/15896501>.

162. Kyrgidis A, Tzellos TG, Kechagias N, et al. Cutaneous squamous cell carcinoma (SCC) of the head and neck: risk factors of overall and recurrence-free survival. *Eur J Cancer* 2010;46:1563-1572. Available at: <http://www.ncbi.nlm.nih.gov/pubmed/20338745>.

163. Han A, Ratner D. What is the role of adjuvant radiotherapy in the treatment of cutaneous squamous cell carcinoma with perineural invasion? *Cancer* 2007;109:1053-1059. Available at: <http://www.ncbi.nlm.nih.gov/pubmed/17279578>.

164. Galloway TJ, Morris CG, Mancuso AA, et al. Impact of radiographic findings on prognosis for skin carcinoma with clinical perineural invasion. *Cancer* 2005;103:1254-1257. Available at: <http://www.ncbi.nlm.nih.gov/pubmed/15693020>.

165. Goepfert H, Dichtel WJ, Medina JE, et al. Perineural invasion in squamous cell skin carcinoma of the head and neck. *Am J Surg* 1984;148:542-547. Available at: <http://www.ncbi.nlm.nih.gov/pubmed/6486325>.

166. Durham AB, Lowe L, Malloy KM, et al. Sentinel Lymph Node Biopsy for Cutaneous Squamous Cell Carcinoma on the Head and Neck. *JAMA Otolaryngol Head Neck Surg* 2016;142:1171-1176. Available at: <https://www.ncbi.nlm.nih.gov/pubmed/27438434>.

167. Gore SM, Shaw D, Martin RC, et al. Prospective study of sentinel node biopsy for high-risk cutaneous squamous cell carcinoma of the head and neck. *Head Neck* 2016;38 Suppl 1:E884-889. Available at: <https://www.ncbi.nlm.nih.gov/pubmed/25965008>.

168. Ampil FL, Hardin JC, Peskind SP, Stucker FJ. Perineural invasion in skin cancer of the head and neck: a review of nine cases. *J Oral Maxillofac Surg* 1995;53:34-38. Available at: <https://www.ncbi.nlm.nih.gov/pubmed/7799119>.



169. Sapir E, Tolpadi A, McHugh J, et al. Skin cancer of the head and neck with gross or microscopic perineural involvement: Patterns of failure. *Radiother Oncol* 2016;120:81-86. Available at: <https://www.ncbi.nlm.nih.gov/pubmed/27475277>.

170. Lin C, Tripcony L, Keller J, et al. Perineural infiltration of cutaneous squamous cell carcinoma and basal cell carcinoma without clinical features. *Int J Radiat Oncol Biol Phys* 2012;82:334-340. Available at: <http://www.ncbi.nlm.nih.gov/pubmed/21093171>.

171. Jackson JE, Dickie GJ, Wiltshire KL, et al. Radiotherapy for perineural invasion in cutaneous head and neck carcinomas: toward a risk-adapted treatment approach. *Head Neck* 2009;31:604-610. Available at: <http://www.ncbi.nlm.nih.gov/pubmed/19132719>.

172. Warren TA, Panizza B, Porceddu SV, et al. Outcomes after surgery and postoperative radiotherapy for perineural spread of head and neck cutaneous squamous cell carcinoma. *Head Neck* 2016;38:824-831. Available at: <https://www.ncbi.nlm.nih.gov/pubmed/25546817>.

173. Thomas SS, Matthews RN. Squamous cell carcinoma of the pinna: a 6-year study. *Br J Plast Surg* 1994;47:81-85. Available at: <http://www.ncbi.nlm.nih.gov/pubmed/8149063>.

174. Endo Y, Tanioka M, Miyachi Y. Prognostic factors in cutaneous squamous cell carcinoma: is patient delay in hospital visit a predictor of survival? *ISRN Dermatol* 2011;2011:285289. Available at: <https://www.ncbi.nlm.nih.gov/pubmed/22363846>.

175. Brinkman JN, Hajder E, van der Holt B, et al. The Effect of Differentiation Grade of Cutaneous Squamous Cell Carcinoma on Excision Margins, Local Recurrence, Metastasis, and Patient Survival: A Retrospective Follow-Up Study. *Ann Plast Surg* 2015;75:323-326. Available at: <https://www.ncbi.nlm.nih.gov/pubmed/24401812>.

176. Cassarino DS, Derienzo DP, Barr RJ. Cutaneous squamous cell carcinoma: a comprehensive clinicopathologic classification--part two. *J Cutan Pathol* 2006;33:261-279. Available at: <http://www.ncbi.nlm.nih.gov/pubmed/16630176>.

177. Banks ER, Cooper PH. Adenosquamous carcinoma of the skin: a report of 10 cases. *J Cutan Pathol* 1991;18:227-234. Available at: <http://www.ncbi.nlm.nih.gov/pubmed/1719048>.

178. Barr RJ. Classification of cutaneous squamous cell carcinoma. *J Cutan Pathol* 1991;18:225-226. Available at: <http://www.ncbi.nlm.nih.gov/pubmed/1939780>.

179. Nappi O, Pettinato G, Wick MR. Adenoid (acantholytic) squamous cell carcinoma of the skin. *J Cutan Pathol* 1989;16:114-121. Available at: <http://www.ncbi.nlm.nih.gov/pubmed/2768593>.

180. Patel NK, McKee PH, Smith NP, Fletcher CD. Primary metaplastic carcinoma (carcinosarcoma) of the skin. A clinicopathologic study of four cases and review of the literature. *Am J Dermatopathol* 1997;19:363-372. Available at: <https://www.ncbi.nlm.nih.gov/pubmed/9261471>.

181. Ogawa T, Kiuru M, Konia TH, Fung MA. Acantholytic squamous cell carcinoma is usually associated with hair follicles, not acantholytic actinic keratosis, and is not "high risk": Diagnosis, management, and clinical outcomes in a series of 115 cases. *J Am Acad Dermatol* 2017;76:327-333. Available at: <https://www.ncbi.nlm.nih.gov/pubmed/27889291>.

182. Garcia C, Crowson AN. Acantholytic squamous cell carcinoma: is it really a more-aggressive tumor? *Dermatol Surg* 2011;37:353-356. Available at: <https://www.ncbi.nlm.nih.gov/pubmed/21410819>.

183. Patel V, Squires SM, Liu DY, Fraga GR. Cutaneous adenosquamous carcinoma: a rare neoplasm with biphasic differentiation. *Cutis* 2014;94:231-233. Available at: <https://www.ncbi.nlm.nih.gov/pubmed/25474451>.

184. Weidner N, Foucar E. Adenosquamous carcinoma of the skin. An aggressive mucin- and gland-forming squamous carcinoma. *Arch Dermatol* 1985;121:775-779. Available at: <https://www.ncbi.nlm.nih.gov/pubmed/2408585>.



185. Breuninger H, Schaumburg-Lever G, Holzschuh J, Horny HP. Desmoplastic squamous cell carcinoma of skin and vermilion surface: a highly malignant subtype of skin cancer. *Cancer* 1997;79:915-919. Available at: <https://www.ncbi.nlm.nih.gov/pubmed/9041153>.

186. Salmon PJ, Hussain W, Geisse JK, et al. Sclerosing squamous cell carcinoma of the skin, an underemphasized locally aggressive variant: a 20-year experience. *Dermatol Surg* 2011;37:664-670. Available at: <http://www.ncbi.nlm.nih.gov/pubmed/21269350>.

187. Griffiths RW, Feeley K, Suvarna SK. Audit of clinical and histological prognostic factors in primary invasive squamous cell carcinoma of the skin: assessment in a minimum 5 year follow-up study after conventional excisional surgery. *Br J Plast Surg* 2002;55:287-292. Available at: <http://www.ncbi.nlm.nih.gov/pubmed/12160533>.

188. College of American Pathologists. Protocol for the Examination of Specimens from Patients with Squamous Cell Carcinoma of the Skin. 2013. Available at: <http://www.cap.org/ShowProperty?nodePath=/UCMCon/Contribution%20Folders/WebContent/pdf/skinsquamous-13protocol-3102.pdf>. Accessed May 12, 2017.

189. Hassanein AM, Proper SA, Depcik-Smith ND, Flowers FP. Peritumoral fibrosis in basal cell and squamous cell carcinoma mimicking perineural invasion: potential pitfall in Mohs micrographic surgery. *Dermatol Surg* 2005;31:1101-1106. Available at: <http://www.ncbi.nlm.nih.gov/pubmed/16164857>.

190. Garcia-Serra A, Hinerman RW, Mendenhall WM, et al. Carcinoma of the skin with perineural invasion. *Head Neck* 2003;25:1027-1033. Available at: <http://www.ncbi.nlm.nih.gov/pubmed/14648861>.

191. Lin C, Tripcony L, Keller J, et al. Cutaneous carcinoma of the head and neck with clinical features of perineural infiltration treated with radiotherapy. *Clin Oncol (R Coll Radiol)* 2013;25:362-367. Available at: <http://www.ncbi.nlm.nih.gov/pubmed/23489870>.

192. Leibovitch I, Huilgol SC, Selva D, et al. Basal cell carcinoma treated with Mohs surgery in Australia III. Perineural invasion. *J Am Acad Dermatol* 2005;53:458-463. Available at: <http://www.ncbi.nlm.nih.gov/pubmed/16112353>.

193. Lawrence N, Cotel WI. Squamous cell carcinoma of skin with perineural invasion. *J Am Acad Dermatol* 1994;31:30-33. Available at: <https://www.ncbi.nlm.nih.gov/pubmed/8021368>.

194. Kadakia S, Ducic Y, Marra D, Saman M. The role of elective superficial parotidectomy in the treatment of temporal region squamous cell carcinoma. *Oral Maxillofac Surg* 2016;20:143-147. Available at: <http://www.ncbi.nlm.nih.gov/pubmed/26685892>.

195. Leibovitch I, Huilgol SC, Selva D, et al. Cutaneous squamous cell carcinoma treated with Mohs micrographic surgery in Australia II. Perineural invasion. *J Am Acad Dermatol* 2005;53:261-266. Available at: <https://www.ncbi.nlm.nih.gov/pubmed/16021121>.

196. Campoli M, Brodland DG, Zitelli J. A prospective evaluation of the clinical, histologic, and therapeutic variables associated with incidental perineural invasion in cutaneous squamous cell carcinoma. *J Am Acad Dermatol* 2014;70:630-636. Available at: <https://www.ncbi.nlm.nih.gov/pubmed/24433872>.

197. Balamucki CJ, DeJesus R, Galloway TJ, et al. Impact of radiographic findings on for prognosis skin cancer with perineural invasion. *Am J Clin Oncol* 2015;38:248-251. Available at: <http://www.ncbi.nlm.nih.gov/pubmed/23648439>.

198. Hortlund M, Arroyo Muhr LS, Storm H, et al. Cancer risks after solid organ transplantation and after long-term dialysis. *Int J Cancer* 2017;140:1091-1101. Available at: <https://www.ncbi.nlm.nih.gov/pubmed/27870055>.



199. Clowry J, Sheridan J, Healy R, et al. Increased non-melanoma skin cancer risk in young patients with inflammatory bowel disease on immunomodulatory therapy: a retrospective single-centre cohort study. *J Eur Acad Dermatol Venereol* 2017;31:978-985. Available at: <https://www.ncbi.nlm.nih.gov/pubmed/28045204>.

200. Sibar S, Findikcioglu K, Erdal AI, et al. Technical Aspects and Difficulties in the Management of Head and Neck Cutaneous Malignancies in Xeroderma Pigmentosum. *Arch Plast Surg* 2016;43:344-351. Available at: <https://www.ncbi.nlm.nih.gov/pubmed/27462567>.

201. Lansbury L, Bath-Hextall F, Perkins W, et al. Interventions for non-metastatic squamous cell carcinoma of the skin: systematic review and pooled analysis of observational studies. *BMJ* 2013;347:f6153. Available at: <https://www.ncbi.nlm.nih.gov/pubmed/24191270>.

202. Chren MM, Linos E, Torres JS, et al. Tumor recurrence 5 years after treatment of cutaneous basal cell carcinoma and squamous cell carcinoma. *J Invest Dermatol* 2013;133:1188-1196. Available at: <http://www.ncbi.nlm.nih.gov/pubmed/23190903>.

203. Honeycutt WM, Jansen GT. Treatment of squamous cell carcinoma of the skin. *Arch Dermatol* 1973;108:670-672. Available at: <http://www.ncbi.nlm.nih.gov/pubmed/4750203>.

204. Shiffman NJ. Squamous cell carcinomas of the skin of the pinna. *Can J Surg* 1975;18:279-283. Available at: <http://www.ncbi.nlm.nih.gov/pubmed/1125865>.

205. Baker NJ, Webb AA, Macpherson D. Surgical management of cutaneous squamous cell carcinoma of the head and neck. *Br J Oral Maxillofac Surg* 2001;39:87-90. Available at: <http://www.ncbi.nlm.nih.gov/pubmed/11286440>.

206. Ang P, Tan AW, Goh CL. Comparison of completely versus incompletely excised cutaneous squamous cell carcinomas. *Ann Acad Med Singapore* 2004;33:68-70. Available at: <http://www.ncbi.nlm.nih.gov/pubmed/15008566>.

207. Nemet AY, Deckel Y, Martin PA, et al. Management of periocular basal and squamous cell carcinoma: a series of 485 cases. *Am J Ophthalmol* 2006;142:293-297. Available at: <http://www.ncbi.nlm.nih.gov/pubmed/16876511>.

208. Mourouzis C, Boynton A, Grant J, et al. Cutaneous head and neck SCCs and risk of nodal metastasis - UK experience. *J Craniomaxillofac Surg* 2009;37:443-447. Available at: <http://www.ncbi.nlm.nih.gov/pubmed/19713116>.

209. van der Eerden PA, Prins ME, Lohuis PJ, et al. Eighteen years of experience in Mohs micrographic surgery and conventional excision for nonmelanoma skin cancer treated by a single facial plastic surgeon and pathologist. *Laryngoscope* 2010;120:2378-2384. Available at: <http://www.ncbi.nlm.nih.gov/pubmed/21046543>.

210. Seretis K, Thomaidis V, Karpouzis A, et al. Epidemiology of surgical treatment of nonmelanoma skin cancer of the head and neck in Greece. *Dermatol Surg* 2010;36:15-22. Available at: <https://www.ncbi.nlm.nih.gov/pubmed/19912277>.

211. Jenkins G, Smith AB, Kanatas AN, et al. Anatomical restrictions in the surgical excision of scalp squamous cell carcinomas: does this affect local recurrence and regional nodal metastases? *Int J Oral Maxillofac Surg* 2014;43:142-146. Available at: <https://www.ncbi.nlm.nih.gov/pubmed/24128939>.

212. Brodland DG, Zitelli JA. Surgical margins for excision of primary cutaneous squamous cell carcinoma. *J Am Acad Dermatol* 1992;27:241-248. Available at: <http://www.ncbi.nlm.nih.gov/pubmed/1430364>.

213. Schell AE, Russell MA, Park SS. Suggested excisional margins for cutaneous malignant lesions based on Mohs micrographic surgery. *JAMA Facial Plast Surg* 2013;15:337-343. Available at: <https://www.ncbi.nlm.nih.gov/pubmed/23744451>.

214. Pugliano-Mauro M, Goldman G. Mohs surgery is effective for high-risk cutaneous squamous cell carcinoma. *Dermatol Surg* 2010;36:1544-1553. Available at: <http://www.ncbi.nlm.nih.gov/pubmed/21053415>.



215. Batra RS, Kelley LC. Predictors of extensive subclinical spread in nonmelanoma skin cancer treated with Mohs micrographic surgery. *Arch Dermatol* 2002;138:1043-1051. Available at: <https://www.ncbi.nlm.nih.gov/pubmed/12164742>.

216. Leibovitch I, Huilgol SC, Selva D, et al. Cutaneous squamous cell carcinoma treated with Mohs micrographic surgery in Australia I. Experience over 10 years. *J Am Acad Dermatol* 2005;53:253-260. Available at: <http://www.ncbi.nlm.nih.gov/pubmed/16021120>.

217. Bogdanov-Berezovsky A, Cohen AD, Glesinger R, et al. Risk factors for incomplete excision of squamous cell carcinomas. *J Dermatolog Treat* 2005;16:341-344. Available at: <https://www.ncbi.nlm.nih.gov/pubmed/16428157>.

218. Tan PY, Ek E, Su S, et al. Incomplete excision of squamous cell carcinoma of the skin: a prospective observational study. *Plast Reconstr Surg* 2007;120:910-916. Available at: <https://www.ncbi.nlm.nih.gov/pubmed/17805118>.

219. Hansen C, Wilkinson D, Hansen M, Soyer HP. Factors contributing to incomplete excision of nonmelanoma skin cancer by Australian general practitioners. *Arch Dermatol* 2009;145:1253-1260. Available at: <https://www.ncbi.nlm.nih.gov/pubmed/19917954>.

220. Mirshams M, Razzaghi M, Noormohammadpour P, et al. Incidence of incomplete excision in surgically treated cutaneous squamous cell carcinoma and identification of the related risk factors. *Acta Med Iran* 2011;49:806-809. Available at: <https://www.ncbi.nlm.nih.gov/pubmed/22174169>.

221. Khan AA, Potter M, Cubitt JJ, et al. Guidelines for the excision of cutaneous squamous cell cancers in the United Kingdom: the best cut is the deepest. *J Plast Reconstr Aesthet Surg* 2013;66:467-471. Available at: <https://www.ncbi.nlm.nih.gov/pubmed/23352886>.

222. Carducci M, Bozzetti M, de Marco G, et al. Preoperative margin detection by digital dermoscopy in the traditional surgical excision of cutaneous squamous cell carcinomas. *J Dermatolog Treat* 2013;24:221-226. Available at: <https://www.ncbi.nlm.nih.gov/pubmed/22390630>.

223. Ribero S, Osella Abate S, Di Capua C, et al. Squamocellular Carcinoma of the Skin: Clinicopathological Features Predicting the Involvement of the Surgical Margins and Review of the Literature. *Dermatology* 2016;232:279-284. Available at: <https://www.ncbi.nlm.nih.gov/pubmed/27028227>.

224. Riml S, Larcher L, Kompatscher P. Complete excision of nonmelanotic skin cancer: a matter of surgical experience. *Ann Plast Surg* 2013;70:66-69. Available at: <https://www.ncbi.nlm.nih.gov/pubmed/21712697>.

225. Bovill ES, Cullen KW, Barrett W, Banwell PE. Clinical and histological findings in re-excision of incompletely excised cutaneous squamous cell carcinoma. *J Plast Reconstr Aesthet Surg* 2009;62:457-461. Available at: <https://www.ncbi.nlm.nih.gov/pubmed/18218349>.

226. Yuan Y, Duff ML, Sammons DL, Wu S. Retrospective chart review of skin cancer presence in the wide excisions. *World J Clin Cases* 2014;2:52-56. Available at: <http://www.ncbi.nlm.nih.gov/pubmed/24653985>.

227. Stewart CM, Garlick J, McMullin J, et al. Surgical Excision of Non-Melanoma Skin Cancer in an Elderly Veteran's Affairs Population. *Plast Reconstr Surg Glob Open* 2014;2:e277. Available at: <https://www.ncbi.nlm.nih.gov/pubmed/25587511>.

228. Turner RJ, Leonard N, Malcolm AJ, et al. A retrospective study of outcome of Mohs' micrographic surgery for cutaneous squamous cell carcinoma using formalin fixed sections. *Br J Dermatol* 2000;142:752-757. Available at: <http://www.ncbi.nlm.nih.gov/pubmed/10792227>.

229. Malhotra R, Huilgol SC, Huynh NT, Selva D. The Australian Mohs database: periocular squamous cell carcinoma. *Ophthalmology* 2004;111:617-623. Available at: <http://www.ncbi.nlm.nih.gov/pubmed/15051191>.



230. Leibovitch I, Huilgol SC, Richards S, et al. Scalp tumors treated with Mohs micrographic surgery: clinical features and surgical outcome. *Dermatol Surg* 2006;32:1369-1374. Available at: <http://www.ncbi.nlm.nih.gov/pubmed/17083590>.

231. Silapunt S, Peterson SR, Goldberg LH. Squamous cell carcinoma of the auricle and Mohs micrographic surgery. *Dermatol Surg* 2005;31:1423-1427. Available at: <http://www.ncbi.nlm.nih.gov/pubmed/16416611>.

232. Skaria AM. Recurrence of basosquamous carcinoma after Mohs micrographic surgery. *Dermatology* 2010;221:352-355. Available at: <http://www.ncbi.nlm.nih.gov/pubmed/20924160>.

233. Koslosky CL, El Tal AK, Workman B, et al. Reliability of skin biopsies in determining accurate tumor margins: a retrospective study after Mohs micrographic surgery. *Dermatol Surg* 2014;40:964-970. Available at: <http://www.ncbi.nlm.nih.gov/pubmed/25099294>.

234. Chambers KJ, Kraft S, Emerick K. Evaluation of frozen section margins in high-risk cutaneous squamous cell carcinomas of the head and neck. *Laryngoscope* 2015;125:636-639. Available at: <https://www.ncbi.nlm.nih.gov/pubmed/25230253>.

235. Castley AJ, Theile DR, Lambie D. The use of frozen section in the excision of cutaneous malignancy: a Queensland experience. *Ann Plast Surg* 2013;71:386-389. Available at: <https://www.ncbi.nlm.nih.gov/pubmed/24025654>.

236. Gayre GS, Hybarger CP, Mannor G, et al. Outcomes of excision of 1750 eyelid and periocular skin basal cell and squamous cell carcinomas by modified en face frozen section margin-controlled technique. *Int Ophthalmol Clin* 2009;49:97-110. Available at: <https://www.ncbi.nlm.nih.gov/pubmed/20348860>.

237. de Visscher JG, Gooris PJ, Vermey A, Roodenburg JL. Surgical margins for resection of squamous cell carcinoma of the lower lip. *Int J Oral Maxillofac Surg* 2002;31:154-157. Available at: <https://www.ncbi.nlm.nih.gov/pubmed/12102412>.

238. Bogdanov-Berezovsky A, Rosenberg L, Cagniano E, Silberstein E. The role of frozen section histological analysis in the treatment of head and neck skin basal and squamous cell carcinomas. *Isr Med Assoc J* 2008;10:344-345. Available at: <https://www.ncbi.nlm.nih.gov/pubmed/18605355>.

239. Moncrieff MD, Shah AK, Igali L, Garioch JJ. False-negative rate of intraoperative frozen section margin analysis for complex head and neck nonmelanoma skin cancer excisions. *Clin Exp Dermatol* 2015;40:834-838. Available at: <http://www.ncbi.nlm.nih.gov/pubmed/26290360>.

240. Ross AS, Schmults CD. Sentinel lymph node biopsy in cutaneous squamous cell carcinoma: a systematic review of the English literature. *Dermatol Surg* 2006;32:1309-1321. Available at: <http://www.ncbi.nlm.nih.gov/pubmed/17083582>.

241. Renzi C, Caggiati A, Mannooranparampil TJ, et al. Sentinel lymph node biopsy for high risk cutaneous squamous cell carcinoma: case series and review of the literature. *Eur J Surg Oncol* 2007;33:364-369. Available at: <https://www.ncbi.nlm.nih.gov/pubmed/17129703>.

242. Kwon S, Dong ZM, Wu PC. Sentinel lymph node biopsy for high-risk cutaneous squamous cell carcinoma: clinical experience and review of literature. *World J Surg Oncol* 2011;9:80. Available at: <https://www.ncbi.nlm.nih.gov/pubmed/21771334>.

243. Ahmed MM, Moore BA, Schmalbach CE. Utility of head and neck cutaneous squamous cell carcinoma sentinel node biopsy: a systematic review. *Otolaryngol Head Neck Surg* 2014;150:180-187. Available at: <http://www.ncbi.nlm.nih.gov/pubmed/24201060>.

244. Fukushima S, Masuguchi S, Igata T, et al. Evaluation of sentinel node biopsy for cutaneous squamous cell carcinoma. *J Dermatol* 2014;41:539-541. Available at: <https://www.ncbi.nlm.nih.gov/pubmed/24909214>.



245. Takahashi A, Imafuku S, Nakayama J, et al. Sentinel node biopsy for high-risk cutaneous squamous cell carcinoma. *Eur J Surg Oncol* 2014;40:1256-1262. Available at: <https://www.ncbi.nlm.nih.gov/pubmed/24953417>.

246. Krediet JT, Beyer M, Lenz K, et al. Sentinel lymph node biopsy and risk factors for predicting metastasis in cutaneous squamous cell carcinoma. *Br J Dermatol* 2015;172:1029-1036. Available at: <http://www.ncbi.nlm.nih.gov/pubmed/25362868>.

247. Maruyama H, Tanaka R, Fujisawa Y, et al. Availability of sentinel lymph node biopsy for cutaneous squamous cell carcinoma. *J Dermatol* 2017;44:431-437. Available at: <https://www.ncbi.nlm.nih.gov/pubmed/27666747>.

248. Allen JE, Stolle LB. Utility of sentinel node biopsy in patients with high-risk cutaneous squamous cell carcinoma. *Eur J Surg Oncol* 2015;41:197-200. Available at: <https://www.ncbi.nlm.nih.gov/pubmed/25468745>.

249. Abbatucci JS, Boulier N, Laforge T, Lozier JC. Radiation therapy of skin carcinomas: results of a hypofractionated irradiation schedule in 675 cases followed more than 2 years. *Radiother Oncol* 1989;14:113-119. Available at: <https://www.ncbi.nlm.nih.gov/pubmed/2710943>.

250. Kwan W, Wilson D, Moravan V. Radiotherapy for locally advanced basal cell and squamous cell carcinomas of the skin. *Int J Radiat Oncol Biol Phys* 2004;60:406-411. Available at: <https://www.ncbi.nlm.nih.gov/pubmed/15380573>.

251. Hernandez-Machin B, Borrego L, Gil-Garcia M, Hernandez BH. Office-based radiation therapy for cutaneous carcinoma: evaluation of 710 treatments. *Int J Dermatol* 2007;46:453-459. Available at: <http://www.ncbi.nlm.nih.gov/pubmed/17472670>.

252. Barysch MJ, Eggmann N, Beyeler M, et al. Long-term recurrence rate of large and difficult to treat cutaneous squamous cell carcinomas after superficial radiotherapy. *Dermatology* 2012;224:59-65. Available at: <https://www.ncbi.nlm.nih.gov/pubmed/22433440>.

253. Cognetta AB, Howard BM, Heaton HP, et al. Superficial x-ray in the treatment of basal and squamous cell carcinomas: a viable option in select patients. *J Am Acad Dermatol* 2012;67:1235-1241. Available at: <http://www.ncbi.nlm.nih.gov/pubmed/22818756>.

254. Schulte KW, Lippold A, Auras C, et al. Soft x-ray therapy for cutaneous basal cell and squamous cell carcinomas. *J Am Acad Dermatol* 2005;53:993-1001. Available at: <http://www.ncbi.nlm.nih.gov/pubmed/16310060>.

255. Grossi Marconi D, da Costa Resende B, Rauber E, et al. Head and Neck Non-Melanoma Skin Cancer Treated By Superficial X-Ray Therapy: An Analysis of 1021 Cases. *PLoS One* 2016;11:e0156544. Available at: <https://www.ncbi.nlm.nih.gov/pubmed/27367229>.

256. Lovett RD, Perez CA, Shapiro SJ, Garcia DM. External irradiation of epithelial skin cancer. *Int J Radiat Oncol Biol Phys* 1990;19:235-242. Available at: <http://www.ncbi.nlm.nih.gov/pubmed/2394605>.

257. McKenna DJ, Morris S, Kurwa H. Treatment-resistant giant unilateral Bowen's disease of the scalp responding to radiotherapy. *Clin Exp Dermatol* 2009;34:85-86. Available at: <https://www.ncbi.nlm.nih.gov/pubmed/19076799>.

258. Cox NH, Dyson P. Wound healing on the lower leg after radiotherapy or cryotherapy of Bowen's disease and other malignant skin lesions. *Br J Dermatol* 1995;133:60-65. Available at: <https://www.ncbi.nlm.nih.gov/pubmed/7669642>.

259. Dupree MT, Kiteley RA, Weismantle K, et al. Radiation therapy for Bowen's disease: lessons for lesions of the lower extremity. *J Am Acad Dermatol* 2001;45:401-404. Available at: <https://www.ncbi.nlm.nih.gov/pubmed/11511838>.

260. Lukas VanderSpek LA, Pond GR, Wells W, Tsang RW. Radiation therapy for Bowen's disease of the skin. *Int J Radiat Oncol Biol Phys* 2005;63:505-510. Available at: <http://www.ncbi.nlm.nih.gov/pubmed/16168842>.



261. Herman JM, Pierce LJ, Sandler HM, et al. Radiotherapy using a water bath in the treatment of Bowen's disease of the digit. *Radiother Oncol* 2008;88:398-402. Available at: <https://www.ncbi.nlm.nih.gov/pubmed/18571754>.

262. Stevens DM, Kopf AW, Gladstein A, Bart RS. Treatment of Bowen's disease with grenz rays. *Int J Dermatol* 1977;16:329-339. Available at: <https://www.ncbi.nlm.nih.gov/pubmed/873668>.

263. Cotel WI. Perineural invasion by squamous-cell carcinoma. *J Dermatol Surg Oncol* 1982;8:589-600. Available at: <https://www.ncbi.nlm.nih.gov/pubmed/6749931>.

264. Balamucki CJ, Mancuso AA, Amdur RJ, et al. Skin carcinoma of the head and neck with perineural invasion. *Am J Otolaryngol* 2012;33:447-454. Available at: <https://www.ncbi.nlm.nih.gov/pubmed/22185685>.

265. Schulte KW, Auras C, Bramkamp G, et al. Late adverse effects after soft X-ray therapy of cutaneous malignancies: pruritus, burning, epiphora and insufficient occlusion of the mouth. *J Eur Acad Dermatol Venereol* 2008;22:555-560. Available at: <https://www.ncbi.nlm.nih.gov/pubmed/18070025>.

266. Rupprecht R, Lippold A, Auras C, et al. Late side-effects with cosmetic relevance following soft X-ray therapy of cutaneous neoplasias. *J Eur Acad Dermatol Venereol* 2007;21:178-185. Available at: <https://www.ncbi.nlm.nih.gov/pubmed/17243952>.

267. Chan S, Dhadda AS, Swindell R. Single fraction radiotherapy for small superficial carcinoma of the skin. *Clin Oncol (R Coll Radiol)* 2007;19:256-259. Available at: <http://www.ncbi.nlm.nih.gov/pubmed/17379488>.

268. Tsao MN, Tsang RW, Liu FF, et al. Radiotherapy management for squamous cell carcinoma of the nasal skin: the Princess Margaret Hospital experience. *Int J Radiat Oncol Biol Phys* 2002;52:973-979. Available at: <https://www.ncbi.nlm.nih.gov/pubmed/11958891>.

269. Locke J, Karimpour S, Young G, et al. Radiotherapy for epithelial skin cancer. *Int J Radiat Oncol Biol Phys* 2001;51:748-755. Available at: <https://www.ncbi.nlm.nih.gov/pubmed/11697321>.

270. Silva JJ, Tsang RW, Panzarella T, et al. Results of radiotherapy for epithelial skin cancer of the pinna: the Princess Margaret Hospital experience, 1982-1993. *Int J Radiat Oncol Biol Phys* 2000;47:451-459. Available at: <https://www.ncbi.nlm.nih.gov/pubmed/10802373>.

271. Lichter MD, Karagas MR, Mott LA, et al. Therapeutic ionizing radiation and the incidence of basal cell carcinoma and squamous cell carcinoma. The New Hampshire Skin Cancer Study Group. *Arch Dermatol* 2000;136:1007-1011. Available at: <http://www.ncbi.nlm.nih.gov/pubmed/10926736>.

272. Perkins JL, Liu Y, Mitby PA, et al. Nonmelanoma skin cancer in survivors of childhood and adolescent cancer: a report from the childhood cancer survivor study. *J Clin Oncol* 2005;23:3733-3741. Available at: <http://www.ncbi.nlm.nih.gov/pubmed/15923570>.

273. Karagas MR, Nelson HH, Zens MS, et al. Squamous cell and basal cell carcinoma of the skin in relation to radiation therapy and potential modification of risk by sun exposure. *Epidemiology* 2007;18:776-784. Available at: <https://www.ncbi.nlm.nih.gov/pubmed/17917604>.

274. Watt TC, Inskip PD, Stratton K, et al. Radiation-related risk of basal cell carcinoma: a report from the Childhood Cancer Survivor Study. *J Natl Cancer Inst* 2012;104:1240-1250. Available at: <http://www.ncbi.nlm.nih.gov/pubmed/22835387>.

275. Karagas MR, McDonald JA, Greenberg ER, et al. Risk of basal cell and squamous cell skin cancers after ionizing radiation therapy. For The Skin Cancer Prevention Study Group. *J Natl Cancer Inst* 1996;88:1848-1853. Available at: <http://www.ncbi.nlm.nih.gov/pubmed/8961975>.



276. Inskip PD, Sigurdson AJ, Veiga L, et al. Radiation-Related New Primary Solid Cancers in the Childhood Cancer Survivor Study: Comparative Radiation Dose Response and Modification of Treatment Effects. *Int J Radiat Oncol Biol Phys* 2016;94:800-807. Available at: <https://www.ncbi.nlm.nih.gov/pubmed/26972653>.

277. Evans DG, Farndon PA, Burnell LD, et al. The incidence of Gorlin syndrome in 173 consecutive cases of medulloblastoma. *Br J Cancer* 1991;64:959-961. Available at: <https://www.ncbi.nlm.nih.gov/pubmed/1931625>.

278. Stavrou T, Bromley CM, Nicholson HS, et al. Prognostic factors and secondary malignancies in childhood medulloblastoma. *J Pediatr Hematol Oncol* 2001;23:431-436. Available at: <https://www.ncbi.nlm.nih.gov/pubmed/11878577>.

279. Kimonis VE, Goldstein AM, Pastakia B, et al. Clinical manifestations in 105 persons with nevoid basal cell carcinoma syndrome. *Am J Med Genet* 1997;69:299-308. Available at: <https://www.ncbi.nlm.nih.gov/pubmed/9096761>.

280. Dinehart SM, Anthony JL, Pollack SV. Basal cell carcinoma in young patients after irradiation for childhood malignancy. *Med Pediatr Oncol* 1991;19:508-510. Available at: <https://www.ncbi.nlm.nih.gov/pubmed/1961139>.

281. Korczak JF, Brahim JS, DiGiovanna JJ, et al. Nevoid basal cell carcinoma syndrome with medulloblastoma in an African-American boy: a rare case illustrating gene-environment interaction. *Am J Med Genet* 1997;69:309-314. Available at: <https://www.ncbi.nlm.nih.gov/pubmed/9096762>.

282. Strong LC. Genetic and environmental interactions. *Cancer* 1977;40:1861-1866. Available at: <https://www.ncbi.nlm.nih.gov/pubmed/332332>.

283. Goldstein AM, Bale SJ, Peck GL, DiGiovanna JJ. Sun exposure and basal cell carcinomas in the nevoid basal cell carcinoma syndrome. *J Am Acad Dermatol* 1993;29:34-41. Available at: <https://www.ncbi.nlm.nih.gov/pubmed/8315076>.

284. Spalek M, Jonska-Gmyrek J, Galecki J. Radiation-induced morphea - a literature review. *J Eur Acad Dermatol Venereol* 2015;29:197-202. Available at: <https://www.ncbi.nlm.nih.gov/pubmed/25174551>.

285. Alhathloul A, Hein R, Andres C, et al. Post-Irradiation Morphea: Case report and review of the literature. *J Dermatol Case Rep* 2012;6:73-77. Available at: <https://www.ncbi.nlm.nih.gov/pubmed/23091583>.

286. Lin A, Abu-Isa E, Griffith KA, Ben-Josef E. Toxicity of radiotherapy in patients with collagen vascular disease. *Cancer* 2008;113:648-653. Available at: <https://www.ncbi.nlm.nih.gov/pubmed/18506734>.

287. Morris MM, Powell SN. Irradiation in the setting of collagen vascular disease: acute and late complications. *J Clin Oncol* 1997;15:2728-2735. Available at: <https://www.ncbi.nlm.nih.gov/pubmed/9215847>.

288. Chao CK, Gerber RM, Perez CA. Reirradiation of recurrent skin cancer of the face. A successful salvage modality. *Cancer* 1995;75:2351-2355. Available at: <http://www.ncbi.nlm.nih.gov/pubmed/7712447>.

289. Griep C, Davelaar J, Scholten AN, et al. Electron beam therapy is not inferior to superficial x-ray therapy in the treatment of skin carcinoma. *Int J Radiat Oncol Biol Phys* 1995;32:1347-1350. Available at: <https://www.ncbi.nlm.nih.gov/pubmed/7635774>.

290. Traenkle HL, Mulay D. Further observations on late radiation necrosis following therapy of skin cancer. The results of fractionation of the total dose. *Arch Dermatol* 1960;81:908-913. Available at: <https://www.ncbi.nlm.nih.gov/pubmed/13839142>.

291. Hliniak A, Maciejewski B, Trott KR. The influence of the number of fractions, overall treatment time and field size on the local control of cancer of the skin. *Br J Radiol* 1983;56:596-598. Available at: <https://www.ncbi.nlm.nih.gov/pubmed/6871613>.



292. McNab AA, Francis IC, Bengner R, Crompton JL. Perineural spread of cutaneous squamous cell carcinoma via the orbit. Clinical features and outcome in 21 cases. *Ophthalmology* 1997;104:1457-1462. Available at: <https://www.ncbi.nlm.nih.gov/pubmed/9307641>.
293. Gluck I, Ibrahim M, Popovtzer A, et al. Skin cancer of the head and neck with perineural invasion: defining the clinical target volumes based on the pattern of failure. *Int J Radiat Oncol Biol Phys* 2009;74:38-46. Available at: <https://www.ncbi.nlm.nih.gov/pubmed/18938044>.
294. Holmes ME, Bomford CK. The use of a short distance cobalt unit in the treatment of primary skin tumours. *Br J Radiol* 1982;55:225-228. Available at: <https://www.ncbi.nlm.nih.gov/pubmed/7066625>.
295. Caccialanza M, Piccinno R, Beretta M, Gnecci L. Results and side effects of dermatologic radiotherapy: a retrospective study of irradiated cutaneous epithelial neoplasms. *J Am Acad Dermatol* 1999;41:589-594. Available at: <http://www.ncbi.nlm.nih.gov/pubmed/10495382>.
296. Zablow AI, Eanelli TR, Sanfilippo LJ. Electron beam therapy for skin cancer of the head and neck. *Head Neck* 1992;14:188-195. Available at: <https://www.ncbi.nlm.nih.gov/pubmed/1587735>.
297. Ahmed I, Berth-Jones J, Charles-Holmes S, et al. Comparison of cryotherapy with curettage in the treatment of Bowen's disease: a prospective study. *Br J Dermatol* 2000;143:759-766. Available at: <https://www.ncbi.nlm.nih.gov/pubmed/11069453>.
298. Hansen JP, Drake AL, Walling HW. Bowen's Disease: a four-year retrospective review of epidemiology and treatment at a university center. *Dermatol Surg* 2008;34:878-883. Available at: <https://www.ncbi.nlm.nih.gov/pubmed/18363722>.
299. Overmark M, Koskenmies S, Pitkanen S. A Retrospective Study of Treatment of Squamous Cell Carcinoma In situ. *Acta Derm Venereol* 2016;96:64-67. Available at: <http://www.ncbi.nlm.nih.gov/pubmed/26073523>.
300. Warshauer E, Warshauer BL. Clearance of basal cell and superficial squamous cell carcinomas after imiquimod therapy. *J Drugs Dermatol* 2008;7:447-451. Available at: <https://www.ncbi.nlm.nih.gov/pubmed/18505136>.
301. Peris K, Micantonio T, Fagnoli MC, et al. Imiquimod 5% cream in the treatment of Bowen's disease and invasive squamous cell carcinoma. *J Am Acad Dermatol* 2006;55:324-327. Available at: <https://www.ncbi.nlm.nih.gov/pubmed/16844522>.
302. Love WE, Bernhard JD, Bordeaux JS. Topical imiquimod or fluorouracil therapy for basal and squamous cell carcinoma: a systematic review. *Arch Dermatol* 2009;145:1431-1438. Available at: <https://www.ncbi.nlm.nih.gov/pubmed/20026854>.
303. Rosen T, Harting M, Gibson M. Treatment of Bowen's disease with topical 5% imiquimod cream: retrospective study. *Dermatol Surg* 2007;33:427-432. Available at: <https://www.ncbi.nlm.nih.gov/pubmed/17430376>.
304. Mackenzie-Wood A, Kossard S, de Launey J, et al. Imiquimod 5% cream in the treatment of Bowen's disease. *J Am Acad Dermatol* 2001;44:462-470. Available at: <https://www.ncbi.nlm.nih.gov/pubmed/11209116>.
305. Chitwood K, Etkorn J, Cohen G. Topical and intralesional treatment of nonmelanoma skin cancer: efficacy and cost comparisons. *Dermatol Surg* 2013;39:1306-1316. Available at: <https://www.ncbi.nlm.nih.gov/pubmed/23915332>.
306. Patel GK, Goodwin R, Chawla M, et al. Imiquimod 5% cream monotherapy for cutaneous squamous cell carcinoma in situ (Bowen's disease): a randomized, double-blind, placebo-controlled trial. *J Am Acad Dermatol* 2006;54:1025-1032. Available at: <http://www.ncbi.nlm.nih.gov/pubmed/16713457>.
307. Bargman H, Hochman J. Topical treatment of Bowen's disease with 5-Fluorouracil. *J Cutan Med Surg* 2003;7:101-105. Available at: <https://www.ncbi.nlm.nih.gov/pubmed/12447619>.



308. Salim A, Leman JA, McColl JH, et al. Randomized comparison of photodynamic therapy with topical 5-fluorouracil in Bowen's disease. *Br J Dermatol* 2003;148:539-543. Available at: <https://www.ncbi.nlm.nih.gov/pubmed/12653747>.

309. Morton C, Horn M, Leman J, et al. Comparison of topical methyl aminolevulinic acid photodynamic therapy with cryotherapy or Fluorouracil for treatment of squamous cell carcinoma in situ: Results of a multicenter randomized trial. *Arch Dermatol* 2006;142:729-735. Available at: <https://www.ncbi.nlm.nih.gov/pubmed/16785375>.

310. Kuflik EG, Gage AA. The five-year cure rate achieved by cryosurgery for skin cancer. *J Am Acad Dermatol* 1991;24:1002-1004. Available at: <http://www.ncbi.nlm.nih.gov/pubmed/1820761>.

311. Fraunfelder FT, Zacarian SA, Limmer BL, Wingfield D. Cryosurgery for malignancies of the eyelid. *Ophthalmology* 1980;87:461-465. Available at: <https://www.ncbi.nlm.nih.gov/pubmed/7413134>.

312. Lindemalm-Lundstam B, Dalenback J. Prospective follow-up after curettage-cryosurgery for scalp and face skin cancers. *Br J Dermatol* 2009;161:568-576. Available at: <https://www.ncbi.nlm.nih.gov/pubmed/19624544>.

313. Holt PJ. Cryotherapy for skin cancer: results over a 5-year period using liquid nitrogen spray cryosurgery. *Br J Dermatol* 1988;119:231-240. Available at: <https://www.ncbi.nlm.nih.gov/pubmed/3166941>.

314. Morton CA, Whitehurst C, Moseley H, et al. Comparison of photodynamic therapy with cryotherapy in the treatment of Bowen's disease. *Br J Dermatol* 1996;135:766-771. Available at: <https://www.ncbi.nlm.nih.gov/pubmed/8977678>.

315. Peikert JM. Prospective trial of curettage and cryosurgery in the management of non-facial, superficial, and minimally invasive basal and squamous cell carcinoma. *Int J Dermatol* 2011;50:1135-1138. Available at: <http://www.ncbi.nlm.nih.gov/pubmed/22126880>.

316. Zacarian SA. Cryosurgery of cutaneous carcinomas. An 18-year study of 3,022 patients with 4,228 carcinomas. *J Am Acad Dermatol* 1983;9:947-956. Available at: <https://www.ncbi.nlm.nih.gov/pubmed/6643791>.

317. Cairnduff F, Stringer MR, Hudson EJ, et al. Superficial photodynamic therapy with topical 5-aminolaevulinic acid for superficial primary and secondary skin cancer. *Br J Cancer* 1994;69:605-608. Available at: <http://www.ncbi.nlm.nih.gov/pubmed/8123497>.

318. Morton CA, Whitehurst C, Moore JV, MacKie RM. Comparison of red and green light in the treatment of Bowen's disease by photodynamic therapy. *Br J Dermatol* 2000;143:767-772. Available at: <https://www.ncbi.nlm.nih.gov/pubmed/11069454>.

319. Morton CA, Whitehurst C, McColl JH, et al. Photodynamic therapy for large or multiple patches of Bowen disease and basal cell carcinoma. *Arch Dermatol* 2001;137:319-324. Available at: <https://www.ncbi.nlm.nih.gov/pubmed/11255332>.

320. Varma S, Wilson H, Kurwa HA, et al. Bowen's disease, solar keratoses and superficial basal cell carcinomas treated by photodynamic therapy using a large-field incoherent light source. *Br J Dermatol* 2001;144:567-574. Available at: <https://www.ncbi.nlm.nih.gov/pubmed/11260016>.

321. Lui H, Hobbs L, Tope WD, et al. Photodynamic therapy of multiple nonmelanoma skin cancers with verteporfin and red light-emitting diodes: two-year results evaluating tumor response and cosmetic outcomes. *Arch Dermatol* 2004;140:26-32. Available at: <https://www.ncbi.nlm.nih.gov/pubmed/14732656>.

322. Haddad R, Neshet E, Weiss J, et al. Photodynamic therapy for Bowen's disease and squamous cell carcinoma of the skin. *Photodiagnosis Photodyn Ther* 2004;1:225-230. Available at: <https://www.ncbi.nlm.nih.gov/pubmed/25048336>.



323. Calzavara-Pinton PG, Venturini M, Sala R, et al. Methylaminolaevulinate-based photodynamic therapy of Bowen's disease and squamous cell carcinoma. *Br J Dermatol* 2008;159:137-144. Available at: <https://www.ncbi.nlm.nih.gov/pubmed/18489606>.

324. Lopez N, Meyer-Gonzalez T, Herrera-Acosta E, et al. Photodynamic therapy in the treatment of extensive Bowen's disease. *J Dermatolog Treat* 2012;23:428-430. Available at: <https://www.ncbi.nlm.nih.gov/pubmed/21787214>.

325. Truchuelo M, Fernandez-Guarino M, Fleta B, et al. Effectiveness of photodynamic therapy in Bowen's disease: an observational and descriptive study in 51 lesions. *J Eur Acad Dermatol Venereol* 2012;26:868-874. Available at: <https://www.ncbi.nlm.nih.gov/pubmed/21740466>.

326. Ko DY, Kim KH, Song KH. A randomized trial comparing methyl aminolaevulinate photodynamic therapy with and without Er:YAG ablative fractional laser treatment in Asian patients with lower extremity Bowen disease: results from a 12-month follow-up. *Br J Dermatol* 2014;170:165-172. Available at: <https://www.ncbi.nlm.nih.gov/pubmed/24102369>.

327. Choi SH, Kim KH, Song KH. Effect of Methyl Aminolevulinic Acid Photodynamic Therapy With and Without Ablative Fractional Laser Treatment in Patients With Microinvasive Squamous Cell Carcinoma: A Randomized Clinical Trial. *JAMA Dermatol* 2017;153:289-295. Available at: <https://www.ncbi.nlm.nih.gov/pubmed/28199463>.

328. Zaar O, Fouglerberg J, Hermansson A, et al. Effectiveness of photodynamic therapy in Bowen's disease: a retrospective observational study in 423 lesions. *J Eur Acad Dermatol Venereol* 2017;31:1289-1294. Available at: <https://www.ncbi.nlm.nih.gov/pubmed/28190258>.

329. Souza CS, Felicio LB, Ferreira J, et al. Long-term follow-up of topical 5-aminolaevulinic acid photodynamic therapy diode laser single session for non-melanoma skin cancer. *Photodiagnosis Photodyn Ther* 2009;6:207-213. Available at: <https://www.ncbi.nlm.nih.gov/pubmed/19932453>.

330. Morton CA, Whitehurst C, Moseley H, et al. Development of an alternative light source to lasers for photodynamic therapy: 3. Clinical evaluation in the treatment of pre-malignant non-melanoma skin cancer. *Lasers in Medical Science* 1995;10:165-171. Available at: <http://dx.doi.org/10.1007/BF02133327>.

331. Moseley H, Ibbotson S, Woods J, et al. Clinical and research applications of photodynamic therapy in dermatology: experience of the Scottish PDT Centre. *Lasers Surg Med* 2006;38:403-416. Available at: <http://www.ncbi.nlm.nih.gov/pubmed/16788933>.

332. Clark C, Bryden A, Dawe R, et al. Topical 5-aminolaevulinic acid photodynamic therapy for cutaneous lesions: outcome and comparison of light sources. *Photodermatol Photoimmunol Photomed* 2003;19:134-141. Available at: <https://www.ncbi.nlm.nih.gov/pubmed/12914598>.

333. Britton JE, Goulden V, Stables G, et al. Investigation of the use of the pulsed dye laser in the treatment of Bowen's disease using 5-aminolaevulinic acid phototherapy. *Br J Dermatol* 2005;153:780-784. Available at: <https://www.ncbi.nlm.nih.gov/pubmed/16181460>.

334. Stephens FO, Harker GJ. The use of intra-arterial chemotherapy for treatment of malignant skin neoplasms. *Australas J Dermatol* 1979;20:99-107. Available at: <https://www.ncbi.nlm.nih.gov/pubmed/539962>.

335. Guthrie TH, Porubsky ES. Successful systemic chemotherapy of advanced squamous and basal cell carcinoma of the skin with cis-diamminedichloroplatinum III and doxorubicin. *Laryngoscope* 1982;92:1298-1299. Available at: <https://www.ncbi.nlm.nih.gov/pubmed/6890609>.

336. Ajani JA, Burgess MA. Multiple squamous cell carcinoma treated with intra-arterial cisplatin in a patient with rheumatoid arthritis. *Cancer Treat Rep* 1982;66:1987-1989. Available at: <https://www.ncbi.nlm.nih.gov/pubmed/6890408>.



337. Merimsky O, Neudorfer M, Spitzer E, Chaitchik S. Salvage cisplatin and adriamycin for advanced or recurrent basal or squamous cell carcinoma of the face. *Anticancer Drugs* 1992;3:481-484. Available at: <https://www.ncbi.nlm.nih.gov/pubmed/1450442>.

338. Fujisawa Y, Umebayashi Y, Ichikawa E, et al. Chemoradiation using low-dose cisplatin and 5-fluorouracil in locally advanced squamous cell carcinoma of the skin: a report of two cases. *J Am Acad Dermatol* 2006;55:S81-85. Available at: <https://www.ncbi.nlm.nih.gov/pubmed/17052540>.

339. Phan R, Phan L, Ginsberg LE, et al. Durable response to chemotherapy for recurrent squamous cell carcinoma of the cheek with perineural spread. *Arch Ophthalmol* 2009;127:1074-1075. Available at: <https://www.ncbi.nlm.nih.gov/pubmed/19667357>.

340. Ikegawa S, Saida T, Obayashi H, et al. Cisplatin combination chemotherapy in squamous cell carcinoma and adenoid cystic carcinoma of the skin. *J Dermatol* 1989;16:227-230. Available at: <https://www.ncbi.nlm.nih.gov/pubmed/2551943>.

341. Khansur T, Kennedy A. Cisplatin and 5-fluorouracil for advanced locoregional and metastatic squamous cell carcinoma of the skin. *Cancer* 1991;67:2030-2032. Available at: <https://www.ncbi.nlm.nih.gov/pubmed/2004320>.

342. Guthrie TH, Jr., Porubsky ES, Luxenberg MN, et al. Cisplatin-based chemotherapy in advanced basal and squamous cell carcinomas of the skin: results in 28 patients including 13 patients receiving multimodality therapy. *J Clin Oncol* 1990;8:342-346. Available at: <http://www.ncbi.nlm.nih.gov/pubmed/2405109>.

343. Sadek H, Azli N, Wendling JL, et al. Treatment of advanced squamous cell carcinoma of the skin with cisplatin, 5-fluorouracil, and bleomycin. *Cancer* 1990;66:1692-1696. Available at: <https://www.ncbi.nlm.nih.gov/pubmed/1698529>.

344. Shin DM, Glisson BS, Khuri FR, et al. Phase II and biologic study of interferon alfa, retinoic acid, and cisplatin in advanced squamous skin cancer. *J Clin Oncol* 2002;20:364-370. Available at: <http://www.ncbi.nlm.nih.gov/pubmed/11786562>.

345. Tanvetyanon T, Padhya T, McCaffrey J, et al. Postoperative concurrent chemotherapy and radiotherapy for high-risk cutaneous squamous cell carcinoma of the head and neck. *Head Neck* 2015;37:840-845. Available at: <https://www.ncbi.nlm.nih.gov/pubmed/24623654>.

346. Jenni D, Karpova MB, Muhleisen B, et al. A prospective clinical trial to assess lapatinib effects on cutaneous squamous cell carcinoma and actinic keratosis. *ESMO Open* 2016;1:e000003. Available at: <https://www.ncbi.nlm.nih.gov/pubmed/27843579>.

347. Reigneau M, Robert C, Routier E, et al. Efficacy of neoadjuvant cetuximab alone or with platinum salt for the treatment of unresectable advanced nonmetastatic cutaneous squamous cell carcinomas. *Br J Dermatol* 2015;173:527-534. Available at: <http://www.ncbi.nlm.nih.gov/pubmed/25704233>.

348. Lu SM, Lien WW. Concurrent Radiotherapy With Cetuximab or Platinum-based Chemotherapy for Locally Advanced Cutaneous Squamous Cell Carcinoma of the Head and Neck. *Am J Clin Oncol* 2015. Available at: <https://www.ncbi.nlm.nih.gov/pubmed/26353121>.

349. Samstein RM, Ho AL, Lee NY, Barker CA. Locally advanced and unresectable cutaneous squamous cell carcinoma: outcomes of concurrent cetuximab and radiotherapy. *J Skin Cancer* 2014;2014:284582. Available at: <https://www.ncbi.nlm.nih.gov/pubmed/25136458>.

350. Heath CH, Deep NL, Nabell L, et al. Phase 1 study of erlotinib plus radiation therapy in patients with advanced cutaneous squamous cell carcinoma. *Int J Radiat Oncol Biol Phys* 2013;85:1275-1281. Available at: <https://www.ncbi.nlm.nih.gov/pubmed/23182701>.



351. Lewis CM, Glisson BS, Feng L, et al. A phase II study of gefitinib for aggressive cutaneous squamous cell carcinoma of the head and neck. *Clin Cancer Res* 2012;18:1435-1446. Available at: <https://www.ncbi.nlm.nih.gov/pubmed/22261807>.

352. Maubec E, Petrow P, Scheer-Senjarich I, et al. Phase II Study of Cetuximab As First-Line Single-Drug Therapy in Patients With Unresectable Squamous Cell Carcinoma of the Skin. *J Clin Oncol* 2011;29:3419-3426. Available at: <http://www.ncbi.nlm.nih.gov/pubmed/21810686>.

353. Jorizzo J, Weiss J, Furst K, et al. Effect of a 1-week treatment with 0.5% topical fluorouracil on occurrence of actinic keratosis after cryosurgery: a randomized, vehicle-controlled clinical trial. *Arch Dermatol* 2004;140:813-816. Available at: <https://www.ncbi.nlm.nih.gov/pubmed/15262691>.

354. Stockfleth E, von Kiedrowski R, Dominicus R, et al. Efficacy and Safety of 5-Fluorouracil 0.5%/Salicylic Acid 10% in the Field-Directed Treatment of Actinic Keratosis: A Phase III, Randomized, Double-Blind, Vehicle-Controlled Trial. *Dermatol Ther (Heidelb)* 2017;7:81-96. Available at: <https://www.ncbi.nlm.nih.gov/pubmed/27995485>.

355. Pomerantz H, Hogan D, Eilers D, et al. Long-term Efficacy of Topical Fluorouracil Cream, 5%, for Treating Actinic Keratosis: A Randomized Clinical Trial. *JAMA Dermatol* 2015;151:952-960. Available at: <https://www.ncbi.nlm.nih.gov/pubmed/25950503>.

356. Rahvar M, Lamel SA, Maibach HI. Randomized, vehicle-controlled trials of topical 5-fluorouracil therapy for actinic keratosis treatment: an overview. *Immunotherapy* 2012;4:939-945. Available at: <https://www.ncbi.nlm.nih.gov/pubmed/23046237>.

357. Stockfleth E, Zwingers T, Willers C. Recurrence rates and patient assessed outcomes of 0.5% 5-fluorouracil in combination with salicylic acid treating actinic keratoses. *Eur J Dermatol* 2012;22:370-374. Available at: <https://www.ncbi.nlm.nih.gov/pubmed/22494856>.

358. Hadley G, Derry S, Moore RA. Imiquimod for actinic keratosis: systematic review and meta-analysis. *J Invest Dermatol* 2006;126:1251-1255. Available at: <http://www.ncbi.nlm.nih.gov/pubmed/16557235>.

359. Gebauer K, Shumack S, Cowen PS. Effect of dosing frequency on the safety and efficacy of imiquimod 5% cream for treatment of actinic keratosis on the forearms and hands: a phase II, randomized placebo-controlled trial. *Br J Dermatol* 2009;161:897-903. Available at: <https://www.ncbi.nlm.nih.gov/pubmed/19545297>.

360. Swanson N, Smith CC, Kaur M, Goldenberg G. Imiquimod 2.5% and 3.75% for the treatment of actinic keratoses: two phase 3, multicenter, randomized, double-blind, placebo-controlled studies. *J Drugs Dermatol* 2014;13:166-169. Available at: <https://www.ncbi.nlm.nih.gov/pubmed/24509967>.

361. Alomar A, Stockfleth E, Dirschka T, et al. Efficacy and Safety of Imiquimod 3.75% from Lmax in Actinic Keratosis According to Fitzpatrick Skin Type. *J Drugs Dermatol* 2016;15:285-289. Available at: <https://www.ncbi.nlm.nih.gov/pubmed/26954313>.

362. Lebwohl M, Swanson N, Anderson LL, et al. Ingenol mebutate gel for actinic keratosis. *N Engl J Med* 2012;366:1010-1019. Available at: <https://www.ncbi.nlm.nih.gov/pubmed/22417254>.

363. Anderson L, Schmieder GJ, Werschler WP, et al. Randomized, double-blind, double-dummy, vehicle-controlled study of ingenol mebutate gel 0.025% and 0.05% for actinic keratosis. *J Am Acad Dermatol* 2009;60:934-943. Available at: <https://www.ncbi.nlm.nih.gov/pubmed/19467365>.

364. Garbe C, Basset-Seguin N, Poulin Y, et al. Efficacy and safety of follow-up field treatment of actinic keratosis with ingenol mebutate 0.015% gel: a randomized, controlled 12-month study. *Br J Dermatol* 2016;174:505-513. Available at: <https://www.ncbi.nlm.nih.gov/pubmed/26471889>.



365. Freeman M, Vinciullo C, Francis D, et al. A comparison of photodynamic therapy using topical methyl aminolevulinate (Metvix) with single cycle cryotherapy in patients with actinic keratosis: a prospective, randomized study. *J Dermatolog Treat* 2003;14:99-106. Available at: <https://www.ncbi.nlm.nih.gov/pubmed/12775317>.

366. Piacquadio DJ, Chen DM, Farber HF, et al. Photodynamic therapy with aminolevulinic acid topical solution and visible blue light in the treatment of multiple actinic keratoses of the face and scalp: investigator-blinded, phase 3, multicenter trials. *Arch Dermatol* 2004;140:41-46. Available at: <https://www.ncbi.nlm.nih.gov/pubmed/14732659>.

367. Hauschild A, Stockfleth E, Popp G, et al. Optimization of photodynamic therapy with a novel self-adhesive 5-aminolaevulinic acid patch: results of two randomized controlled phase III studies. *Br J Dermatol* 2009;160:1066-1074. Available at: <https://www.ncbi.nlm.nih.gov/pubmed/19222455>.

368. Szeimies RM, Matheson RT, Davis SA, et al. Topical methyl aminolevulinate photodynamic therapy using red light-emitting diode light for multiple actinic keratoses: a randomized study. *Dermatol Surg* 2009;35:586-592. Available at: <https://www.ncbi.nlm.nih.gov/pubmed/19309347>.

369. Szeimies RM, Radny P, Sebastian M, et al. Photodynamic therapy with BF-200 ALA for the treatment of actinic keratosis: results of a prospective, randomized, double-blind, placebo-controlled phase III study. *Br J Dermatol* 2010;163:386-394. Available at: <https://www.ncbi.nlm.nih.gov/pubmed/20518784>.

370. Szeimies RM, Stockfleth E, Popp G, et al. Long-term follow-up of photodynamic therapy with a self-adhesive 5-aminolaevulinic acid patch: 12 months data. *Br J Dermatol* 2010;162:410-414. Available at: <https://www.ncbi.nlm.nih.gov/pubmed/19804593>.

371. Dirschka T, Radny P, Dominicus R, et al. Long-term (6 and 12 months) follow-up of two prospective, randomized, controlled phase III trials of photodynamic therapy with BF-200 ALA and methyl aminolaevulinate for the treatment of actinic keratosis. *Br J Dermatol* 2013;168:825-836. Available at: <https://www.ncbi.nlm.nih.gov/pubmed/23252768>.

372. Pariser DM, Houlihan A, Ferdon MB, et al. Randomized Vehicle-Controlled Study of Short Drug Incubation Aminolevulinic Acid Photodynamic Therapy for Actinic Keratoses of the Face or Scalp. *Dermatol Surg* 2016;42:296-304. Available at: <https://www.ncbi.nlm.nih.gov/pubmed/26863596>.

373. Gupta AK, Paquet M. Network meta-analysis of the outcome 'participant complete clearance' in nonimmunosuppressed participants of eight interventions for actinic keratosis: a follow-up on a Cochrane review. *Br J Dermatol* 2013;169:250-259. Available at: <https://www.ncbi.nlm.nih.gov/pubmed/23550994>.

374. Gupta AK, Paquet M, Villanueva E, Brintnell W. Interventions for actinic keratoses. *Cochrane Database Syst Rev* 2012;12:CD004415. Available at: <https://www.ncbi.nlm.nih.gov/pubmed/23235610>.

375. McEwan LE, Smith JG. Topical diclofenac/hyaluronic acid gel in the treatment of solar keratoses. *Australas J Dermatol* 1997;38:187-189. Available at: <https://www.ncbi.nlm.nih.gov/pubmed/9431711>.

376. Rivers JK, Arlette J, Shear N, et al. Topical treatment of actinic keratoses with 3.0% diclofenac in 2.5% hyaluronan gel. *Br J Dermatol* 2002;146:94-100. Available at: <https://www.ncbi.nlm.nih.gov/pubmed/11841372>.

377. Gebauer K, Brown P, Varigos G. Topical diclofenac in hyaluronan gel for the treatment of solar keratoses. *Australas J Dermatol* 2003;44:40-43. Available at: <https://www.ncbi.nlm.nih.gov/pubmed/12581080>.



378. Zane C, Facchinetti E, Rossi MT, et al. A randomized clinical trial of photodynamic therapy with methyl aminolaevulinate vs. diclofenac 3% plus hyaluronic acid gel for the treatment of multiple actinic keratoses of the face and scalp. *Br J Dermatol* 2014;170:1143-1150. Available at: <https://www.ncbi.nlm.nih.gov/pubmed/24506666>.

379. Stockfleth E, Kerl H, Zwingers T, Willers C. Low-dose 5-fluorouracil in combination with salicylic acid as a new lesion-directed option to treat topically actinic keratoses: histological and clinical study results. *Br J Dermatol* 2011;165:1101-1108. Available at: <https://www.ncbi.nlm.nih.gov/pubmed/21517801>.

380. Szeimies RM, Karrer S, Radakovic-Fijan S, et al. Photodynamic therapy using topical methyl 5-aminolevulinate compared with cryotherapy for actinic keratosis: A prospective, randomized study. *J Am Acad Dermatol* 2002;47:258-262. Available at: <https://www.ncbi.nlm.nih.gov/pubmed/12140473>.

381. Morton C, Campbell S, Gupta G, et al. Intraindividual, right-left comparison of topical methyl aminolaevulinate-photodynamic therapy and cryotherapy in subjects with actinic keratoses: a multicentre, randomized controlled study. *Br J Dermatol* 2006;155:1029-1036. Available at: <https://www.ncbi.nlm.nih.gov/pubmed/17034536>.

382. Kaufmann R, Spelman L, Weightman W, et al. Multicentre intraindividual randomized trial of topical methyl aminolaevulinate-photodynamic therapy vs. cryotherapy for multiple actinic keratoses on the extremities. *Br J Dermatol* 2008;158:994-999. Available at: <https://www.ncbi.nlm.nih.gov/pubmed/18341663>.

383. Serra-Guillen C, Nagore E, Hueso L, et al. A randomized pilot comparative study of topical methyl aminolevulinate photodynamic therapy versus imiquimod 5% versus sequential application of both therapies in immunocompetent patients with actinic keratosis: clinical and histologic outcomes. *J Am Acad Dermatol* 2012;66:e131-137. Available at: <https://www.ncbi.nlm.nih.gov/pubmed/22226430>.

384. Hadley J, Tristani-Firouzi P, Hull C, et al. Results of an investigator-initiated single-blind split-face comparison of photodynamic therapy and 5% imiquimod cream for the treatment of actinic keratoses. *Dermatol Surg* 2012;38:722-727. Available at: <https://www.ncbi.nlm.nih.gov/pubmed/22340282>.

385. Smith S, Piacquadio D, Morhenn V, et al. Short incubation PDT versus 5-FU in treating actinic keratoses. *J Drugs Dermatol* 2003;2:629-635. Available at: <https://www.ncbi.nlm.nih.gov/pubmed/14711141>.

386. Kurwa HA, Yong-Gee SA, Seed PT, et al. A randomized paired comparison of photodynamic therapy and topical 5-fluorouracil in the treatment of actinic keratoses. *J Am Acad Dermatol* 1999;41:414-418. Available at: <https://www.ncbi.nlm.nih.gov/pubmed/10459115>.

387. Sotiriou E, Apalla Z, Maliamani F, et al. Intraindividual, right-left comparison of topical 5-aminolevulinic acid photodynamic therapy vs. 5% imiquimod cream for actinic keratoses on the upper extremities. *J Eur Acad Dermatol Venereol* 2009;23:1061-1065. Available at: <http://www.ncbi.nlm.nih.gov/pubmed/19470041>.

388. Moggio E, Arisi M, Zane C, et al. A randomized split-face clinical trial analyzing daylight photodynamic therapy with methyl aminolaevulinate vs ingenol mebutate gel for the treatment of multiple actinic keratoses of the face and the scalp. *Photodiagnosis Photodyn Ther* 2016;16:161-165. Available at: <https://www.ncbi.nlm.nih.gov/pubmed/27530375>.

389. Zane C, Fabiano A, Arisi M, Calzavara-Pinton P. A Randomized Split-Face Clinical Trial of Photodynamic Therapy with Methyl Aminolevulinate versus Ingenol Mebutate Gel for the Treatment of Multiple Actinic Keratoses of the Face and Scalp. *Dermatology* 2016;232:472-477. Available at: <https://www.ncbi.nlm.nih.gov/pubmed/27578305>.

390. Berman B, Nestor MS, Newburger J, et al. Treatment of facial actinic keratoses with aminolevulinic acid photodynamic therapy (ALA-PDT) or ingenol mebutate 0.015% gel with and without prior treatment with ALA-PDT. *J Drugs Dermatol* 2014;13:1353-1356. Available at: <https://www.ncbi.nlm.nih.gov/pubmed/25607702>.



391. Simon JC, Dominicus R, Karl L, et al. A prospective randomized exploratory study comparing the efficacy of once-daily topical 0.5% 5-fluorouracil in combination with 10.0% salicylic acid (5-FU/SA) vs. cryosurgery for the treatment of hyperkeratotic actinic keratosis. *J Eur Acad Dermatol Venereol* 2015;29:881-889. Available at: <https://www.ncbi.nlm.nih.gov/pubmed/25257941>.

392. Krawtchenko N, Roewert-Huber J, Ulrich M, et al. A randomised study of topical 5% imiquimod vs. topical 5-fluorouracil vs. cryosurgery in immunocompetent patients with actinic keratoses: a comparison of clinical and histological outcomes including 1-year follow-up. *Br J Dermatol* 2007;157 Suppl 2:34-40. Available at: <https://www.ncbi.nlm.nih.gov/pubmed/18067630>.

393. Foley P, Merlin K, Cumming S, et al. A comparison of cryotherapy and imiquimod for treatment of actinic keratoses: lesion clearance, safety, and skin quality outcomes. *J Drugs Dermatol* 2011;10:1432-1438. Available at: <https://www.ncbi.nlm.nih.gov/pubmed/22134568>.

394. Tanghetti E, Werschler P. Comparison of 5% 5-fluorouracil cream and 5% imiquimod cream in the management of actinic keratoses on the face and scalp. *J Drugs Dermatol* 2007;6:144-147. Available at: <http://www.ncbi.nlm.nih.gov/pubmed/17373172>.

395. Samorano LP, Torezan LA, Sanches JA. Evaluation of the tolerability and safety of a 0.015% ingenol mebutate gel compared to 5% 5-fluorouracil cream for the treatment of facial actinic keratosis: a prospective randomized trial. *J Eur Acad Dermatol Venereol* 2015;29:1822-1827. Available at: <https://www.ncbi.nlm.nih.gov/pubmed/25727104>.

396. Stockfleth E, Sibbring GC, Alarcon I. New Topical Treatment Options for Actinic Keratosis: A Systematic Review. *Acta Derm Venereol* 2016;96:17-22. Available at: <https://www.ncbi.nlm.nih.gov/pubmed/26068001>.

397. Zane C, Facchinetti E, Rossi MT, et al. Cryotherapy is preferable to ablative CO2 laser for the treatment of isolated actinic keratoses of the face and scalp: a randomized clinical trial. *Br J Dermatol* 2014;170:1114-1121. Available at: <https://www.ncbi.nlm.nih.gov/pubmed/24472087>.

398. Ostertag JU, Quaedvlieg PJ, van der Geer S, et al. A clinical comparison and long-term follow-up of topical 5-fluorouracil versus laser resurfacing in the treatment of widespread actinic keratoses. *Lasers Surg Med* 2006;38:731-739. Available at: <https://www.ncbi.nlm.nih.gov/pubmed/16912977>.

399. Scola N, Terras S, Georgas D, et al. A randomized, half-side comparative study of aminolaevulinate photodynamic therapy vs. CO(2) laser ablation in immunocompetent patients with multiple actinic keratoses. *Br J Dermatol* 2012;167:1366-1373. Available at: <https://www.ncbi.nlm.nih.gov/pubmed/22708798>.

400. Holzer G, Pinkowicz A, Radakovic S, et al. Randomized controlled trial comparing 35% trichloroacetic acid peel and 5-aminolaevulinic acid photodynamic therapy for treating multiple actinic keratosis. *Br J Dermatol* 2017;176:1155-1161. Available at: <https://www.ncbi.nlm.nih.gov/pubmed/28012181>.

401. Di Nuzzo S, Cortelazzi C, Boccaletti V, et al. Comparative study of trichloroacetic acid vs. photodynamic therapy with topical 5-aminolevulinic acid for actinic keratosis of the scalp. *Photodermatol Photoimmunol Photomed* 2015;31:233-238. Available at: <https://www.ncbi.nlm.nih.gov/pubmed/25660106>.

402. Lawrence N, Cox SE, Cockerell CJ, et al. A comparison of the efficacy and safety of Jessner's solution and 35% trichloroacetic acid vs 5% fluorouracil in the treatment of widespread facial actinic keratoses. *Arch Dermatol* 1995;131:176-181. Available at: <https://www.ncbi.nlm.nih.gov/pubmed/7857114>.



403. Witheiler DD, Lawrence N, Cox SE, et al. Long-term efficacy and safety of Jessner's solution and 35% trichloroacetic acid vs 5% fluorouracil in the treatment of widespread facial actinic keratoses. *Dermatol Surg* 1997;23:191-196. Available at:

<https://www.ncbi.nlm.nih.gov/pubmed/9145962>.

404. Hantash BM, Stewart DB, Cooper ZA, et al. Facial resurfacing for nonmelanoma skin cancer prophylaxis. *Arch Dermatol* 2006;142:976-982.

Available at: <https://www.ncbi.nlm.nih.gov/pubmed/16924046>.

405. Whitaker DC. Microscopically proven cure of actinic cheilitis by CO2 laser. *Lasers Surg Med* 1987;7:520-523. Available at:

<https://www.ncbi.nlm.nih.gov/pubmed/3431329>.

406. Robinson JK. Actinic cheilitis. A prospective study comparing four treatment methods. *Arch Otolaryngol Head Neck Surg* 1989;115:848-852.

Available at: <https://www.ncbi.nlm.nih.gov/pubmed/2736096>.

407. Laws RA, Wilde JL, Grabski WJ. Comparison of electrodesiccation with CO2 laser for the treatment of actinic cheilitis. *Dermatol Surg* 2000;26:349-353. Available at:

<https://www.ncbi.nlm.nih.gov/pubmed/10759824>.

408. Satorres Nieto M, Gargallo Albiol J, Gay Escoda C. Surgical management of actinic cheilitis. *Med Oral* 2001;6:205-217. Available at:

<https://www.ncbi.nlm.nih.gov/pubmed/11500638>.

409. Alexiades-Armenakas MR, Geronemus RG. Laser-mediated photodynamic therapy of actinic cheilitis. *J Drugs Dermatol* 2004;3:548-551. Available at:

<https://www.ncbi.nlm.nih.gov/pubmed/15552607>.

410. de Godoy Peres FF, Aigotti Haberbeck Brandao A, Rodarte Carvalho Y, et al. A study of actinic cheilitis treatment by two low-morbidity CO2 laser vaporization one-pass protocols. *Lasers Med Sci* 2009;24:375-385.

Available at: <https://www.ncbi.nlm.nih.gov/pubmed/18553116>.

411. Sotiriou E, Apalla Z, Chovarda E, et al. Photodynamic therapy with 5-aminolevulinic acid in actinic cheilitis: an 18-month clinical and histological follow-up. *Journal of the European Academy of Dermatology and Venereology* 2009;24:916-920. Available at:

<https://www.ncbi.nlm.nih.gov/pubmed/20028448>.

412. Lima Gda S, Silva GF, Gomes AP, et al. Diclofenac in hyaluronic acid gel: an alternative treatment for actinic cheilitis. *J Appl Oral Sci* 2010;18:533-537. Available at:

<https://www.ncbi.nlm.nih.gov/pubmed/21085813>.

413. Sotiriou E, Lallas A, Goussi C, et al. Sequential use of photodynamic therapy and imiquimod 5% cream for the treatment of actinic cheilitis: a 12-month follow-up study. *Br J Dermatol* 2011;165:888-892. Available at:

<https://www.ncbi.nlm.nih.gov/pubmed/21916880>.

414. Choi SH, Kim KH, Song KH. Efficacy of ablative fractional laser-assisted photodynamic therapy for the treatment of actinic cheilitis: 12-month follow-up results of a prospective, randomized, comparative trial. *Br J Dermatol* 2015;173:184-191. Available at:

<https://www.ncbi.nlm.nih.gov/pubmed/25400009>.

415. Suarez-Perez JA, Lopez-Navarro N, Herrera-Acosta E, et al. Treatment of actinic cheilitis with methyl aminolevulinate photodynamic therapy and light fractionation: a prospective study of 10 patients. *Eur J Dermatol* 2015;25:623-624. Available at:

<https://www.ncbi.nlm.nih.gov/pubmed/26677980>.

416. Chaves YN, Torezan LA, Lourenco SV, Neto CF. Evaluation of the efficacy of photodynamic therapy for the treatment of actinic cheilitis. *Photodermatol Photoimmunol Photomed* 2017;33:14-21. Available at:

<https://www.ncbi.nlm.nih.gov/pubmed/27864997>.

417. Jambusaria-Pahlajani A, Hess SD, Katz KA, et al. Uncertainty in the perioperative management of high-risk cutaneous squamous cell carcinoma among Mohs surgeons. *Arch Dermatol* 2010;146:1225-1231.

Available at: <https://www.ncbi.nlm.nih.gov/pubmed/21079057>.



418. Martinez JC, Otley CC, Stasko T, et al. Defining the clinical course of metastatic skin cancer in organ transplant recipients: a multicenter collaborative study. *Arch Dermatol* 2003;139:301-306. Available at: <https://www.ncbi.nlm.nih.gov/pubmed/12622621>.
419. Carucci JA, Martinez JC, Zeitouni NC, et al. In-transit metastasis from primary cutaneous squamous cell carcinoma in organ transplant recipients and nonimmunosuppressed patients: clinical characteristics, management, and outcome in a series of 21 patients. *Dermatol Surg* 2004;30:651-655. Available at: <https://www.ncbi.nlm.nih.gov/pubmed/15061850>.
420. Bordea C, Wojnarowska F, Millard PR, et al. Skin cancers in renal-transplant recipients occur more frequently than previously recognized in a temperate climate. *Transplantation* 2004;77:574-579. Available at: <http://www.ncbi.nlm.nih.gov/pubmed/15084938>.
421. Fortina AB, Piaserico S, Caforio AL, et al. Immunosuppressive level and other risk factors for basal cell carcinoma and squamous cell carcinoma in heart transplant recipients. *Arch Dermatol* 2004;140:1079-1085. Available at: <http://www.ncbi.nlm.nih.gov/pubmed/15381547>.
422. McGeown MG, Douglas JF, Middleton D. One thousand renal transplants at Belfast City Hospital: post-graft neoplasia 1968-1999, comparing azathioprine only with cyclosporin-based regimes in a single centre. *Clin Transpl* 2000:193-202. Available at: <http://www.ncbi.nlm.nih.gov/pubmed/11512313>.
423. Euvrard S, Morelon E, Rostaing L, et al. Sirolimus and secondary skin-cancer prevention in kidney transplantation. *N Engl J Med* 2012;367:329-339. Available at: <https://www.ncbi.nlm.nih.gov/pubmed/22830463>.
424. Campbell SB, Walker R, Tai SS, et al. Randomized controlled trial of sirolimus for renal transplant recipients at high risk for nonmelanoma skin cancer. *Am J Transplant* 2012;12:1146-1156. Available at: <http://www.ncbi.nlm.nih.gov/pubmed/22420843>.
425. Salgo R, Gossmann J, Schofer H, et al. Switch to a sirolimus-based immunosuppression in long-term renal transplant recipients: reduced rate of (pre-)malignancies and nonmelanoma skin cancer in a prospective, randomized, assessor-blinded, controlled clinical trial. *Am J Transplant* 2010;10:1385-1393. Available at: <http://www.ncbi.nlm.nih.gov/pubmed/20121752>.
426. Alberu J, Pascoe MD, Campistol JM, et al. Lower malignancy rates in renal allograft recipients converted to sirolimus-based, calcineurin inhibitor-free immunotherapy: 24-month results from the CONVERT trial. *Transplantation* 2011;92:303-310. Available at: <https://www.ncbi.nlm.nih.gov/pubmed/21792049>.
427. Campistol JM, Eris J, Oberbauer R, et al. Sirolimus therapy after early cyclosporine withdrawal reduces the risk for cancer in adult renal transplantation. *J Am Soc Nephrol* 2006;17:581-589. Available at: <https://www.ncbi.nlm.nih.gov/pubmed/16434506>.
428. Hoogendijk-van den Akker JM, Harden PN, Hoitsma AJ, et al. Two-year randomized controlled prospective trial converting treatment of stable renal transplant recipients with cutaneous invasive squamous cell carcinomas to sirolimus. *J Clin Oncol* 2013;31:1317-1323. Available at: <https://www.ncbi.nlm.nih.gov/pubmed/23358973>.
429. Tedesco-Silva H, Peddi VR, Sanchez-Fructuoso A, et al. Open-Label, Randomized Study of Transition From Tacrolimus to Sirolimus Immunosuppression in Renal Allograft Recipients. *Transplant Direct* 2016;2:e69. Available at: <https://www.ncbi.nlm.nih.gov/pubmed/27500260>.
430. Gu YH, Du JX, Ma ML. Sirolimus and non-melanoma skin cancer prevention after kidney transplantation: a meta-analysis. *Asian Pac J Cancer Prev* 2012;13:4335-4339. Available at: <https://www.ncbi.nlm.nih.gov/pubmed/23167339>.
431. Lim WH, Russ GR, Wong G, et al. The risk of cancer in kidney transplant recipients may be reduced in those maintained on everolimus and reduced cyclosporine. *Kidney Int* 2017;91:954-963. Available at: <https://www.ncbi.nlm.nih.gov/pubmed/28109543>.



432. Endrizzi B, Ahmed RL, Ray T, et al. Capecitabine to reduce nonmelanoma skin carcinoma burden in solid organ transplant recipients. *Dermatol Surg* 2013;39:634-645. Available at: <http://www.ncbi.nlm.nih.gov/pubmed/23379978>.

433. Shuttleworth D, Marks R, Griffin PJ, Salaman JR. Treatment of cutaneous neoplasia with etretinate in renal transplant recipients. *Q J Med* 1988;68:717-725. Available at: <https://www.ncbi.nlm.nih.gov/pubmed/3076965>.

434. Bavinck JN, Tieben LM, Van der Woude FJ, et al. Prevention of skin cancer and reduction of keratotic skin lesions during acitretin therapy in renal transplant recipients: a double-blind, placebo-controlled study. *J Clin Oncol* 1995;13:1933-1938. Available at: <https://www.ncbi.nlm.nih.gov/pubmed/7636533>.

435. Gibson GE, O'Grady A, Kay EW, Murphy GM. Low-dose retinoid therapy for chemoprophylaxis of skin cancer in renal transplant recipients. *J Eur Acad Dermatol Venereol* 1998;10:42-47. Available at: <https://www.ncbi.nlm.nih.gov/pubmed/9552756>.

436. McKenna DB, Murphy GM. Skin cancer chemoprophylaxis in renal transplant recipients: 5 years of experience using low-dose acitretin. *Br J Dermatol* 1999;140:656-660. Available at: <https://www.ncbi.nlm.nih.gov/pubmed/10233316>.

437. George R, Weightman W, Russ GR, et al. Acitretin for chemoprevention of non-melanoma skin cancers in renal transplant recipients. *Australas J Dermatol* 2002;43:269-273. Available at: <http://www.ncbi.nlm.nih.gov/pubmed/12423433>.

438. de Sevaux RG, Smit JV, de Jong EM, et al. Acitretin treatment of premalignant and malignant skin disorders in renal transplant recipients: clinical effects of a randomized trial comparing two doses of acitretin. *J Am Acad Dermatol* 2003;49:407-412. Available at: <https://www.ncbi.nlm.nih.gov/pubmed/12963902>.

439. Kraemer KH, DiGiovanna JJ, Moshell AN, et al. Prevention of skin cancer in xeroderma pigmentosum with the use of oral isotretinoin. *N Engl J Med* 1988;318:1633-1637. Available at: <https://www.ncbi.nlm.nih.gov/pubmed/3287161>.

440. Nijsten TE, Stern RS. Oral retinoid use reduces cutaneous squamous cell carcinoma risk in patients with psoriasis treated with psoralen-UVA: a nested cohort study. *J Am Acad Dermatol* 2003;49:644-650. Available at: <http://www.ncbi.nlm.nih.gov/pubmed/14512910>.

441. Moon TE, Levine N, Cartmel B, et al. Effect of retinol in preventing squamous cell skin cancer in moderate-risk subjects: a randomized, double-blind, controlled trial. Southwest Skin Cancer Prevention Study Group. *Cancer Epidemiol Biomarkers Prev* 1997;6:949-956. Available at: <https://www.ncbi.nlm.nih.gov/pubmed/9367069>.

442. Levine N, Moon TE, Cartmel B, et al. Trial of retinol and isotretinoin in skin cancer prevention: a randomized, double-blind, controlled trial. Southwest Skin Cancer Prevention Study Group. *Cancer Epidemiol Biomarkers Prev* 1997;6:957-961. Available at: <https://www.ncbi.nlm.nih.gov/pubmed/9367070>.

443. Kadakia KC, Barton DL, Loprinzi CL, et al. Randomized controlled trial of acitretin versus placebo in patients at high-risk for basal cell or squamous cell carcinoma of the skin (North Central Cancer Treatment Group Study 969251). *Cancer* 2012;118:2128-2137. Available at: <http://www.ncbi.nlm.nih.gov/pubmed/21882176>.

444. Meyskens FL, Jr., Gilmartin E, Alberts DS, et al. Activity of isotretinoin against squamous cell cancers and preneoplastic lesions. *Cancer Treat Rep* 1982;66:1315-1319. Available at: <https://www.ncbi.nlm.nih.gov/pubmed/6211233>.

445. Prescribing information: SORITANE (acitretin) capsules. 2015. Available at: [https://www.accessdata.fda.gov/drugsatfda\\_docs/label/2014/019821s0241.pdf](https://www.accessdata.fda.gov/drugsatfda_docs/label/2014/019821s0241.pdf). Accessed May 23, 2017.



446. Prescribing information: ABSORICA (isotretinoin) capsules, for oral use. 2015. Available at: [https://www.accessdata.fda.gov/drugsatfda\\_docs/label/2012/021951s000bl.pdf](https://www.accessdata.fda.gov/drugsatfda_docs/label/2012/021951s000bl.pdf). Accessed May 23, 2017.

447. Prescribing information: ACCUTANE (isotretinoin capsules). 2010. Available at: [https://www.accessdata.fda.gov/drugsatfda\\_docs/label/2010/018662s060bl.pdf](https://www.accessdata.fda.gov/drugsatfda_docs/label/2010/018662s060bl.pdf). Accessed May 23, 2017.

448. Weinstock MA, Bingham SF, Digiovanna JJ, et al. Tretinoin and the prevention of keratinocyte carcinoma (Basal and squamous cell carcinoma of the skin): a veterans affairs randomized chemoprevention trial. *J Invest Dermatol* 2012;132:1583-1590. Available at: <http://www.ncbi.nlm.nih.gov/pubmed/22318383>.

449. Tang JY, Chiou AS, Mackay-Wiggan JM, et al. Tazarotene: randomized, double-blind, vehicle-controlled, and open-label concurrent trials for basal cell carcinoma prevention and therapy in patients with basal cell nevus syndrome. *Cancer Prev Res (Phila)* 2014;7:292-299. Available at: <https://www.ncbi.nlm.nih.gov/pubmed/24441673>.

450. Chen AC, Martin AJ, Choy B, et al. A Phase 3 Randomized Trial of Nicotinamide for Skin-Cancer Chemoprevention. *N Engl J Med* 2015;373:1618-1626. Available at: <http://www.ncbi.nlm.nih.gov/pubmed/26488693>.

451. Elmets CA, Viner JL, Pentland AP, et al. Chemoprevention of nonmelanoma skin cancer with celecoxib: a randomized, double-blind, placebo-controlled trial. *J Natl Cancer Inst* 2010;102:1835-1844. Available at: <https://www.ncbi.nlm.nih.gov/pubmed/21115882>.

452. Asgari MM, Chren MM, Warton EM, et al. Association between nonsteroidal anti-inflammatory drug use and cutaneous squamous cell carcinoma. *Arch Dermatol* 2010;146:388-395. Available at: <https://www.ncbi.nlm.nih.gov/pubmed/20157019>.

453. Johannesdottir SA, Chang ET, Mehnert F, et al. Nonsteroidal anti-inflammatory drugs and the risk of skin cancer: a population-based case-control study. *Cancer* 2012;118:4768-4776. Available at: <https://www.ncbi.nlm.nih.gov/pubmed/22644960>.

454. Zhang B, Liang X, Ye L, Wang Y. No chemopreventive effect of nonsteroidal anti-inflammatory drugs on nonmelanoma skin cancer: evidence from meta-analysis. *PLoS One* 2014;9:e96887. Available at: <https://www.ncbi.nlm.nih.gov/pubmed/24828489>.

455. Arber N, Spicak J, Racz I, et al. Five-year analysis of the prevention of colorectal sporadic adenomatous polyps trial. *Am J Gastroenterol* 2011;106:1135-1146. Available at: <https://www.ncbi.nlm.nih.gov/pubmed/21503000>.

456. Bertagnolli MM, Eagle CJ, Zauber AG, et al. Five-year efficacy and safety analysis of the Adenoma Prevention with Celecoxib Trial. *Cancer Prev Res (Phila)* 2009;2:310-321. Available at: <https://www.ncbi.nlm.nih.gov/pubmed/19336730>.

457. Prescribing information: Celebrex (celecoxib) capsules, for oral use. 2016. Available at: [https://www.accessdata.fda.gov/drugsatfda\\_docs/label/2016/020998s048bl.pdf](https://www.accessdata.fda.gov/drugsatfda_docs/label/2016/020998s048bl.pdf). Accessed Sept 7, 2017.

458. Eide MJ, Weinstock MA, Dufresne RG, Jr., et al. Relationship of treatment delay with surgical defect size from keratinocyte carcinoma (basal cell carcinoma and squamous cell carcinoma of the skin). *J Invest Dermatol* 2005;124:308-314. Available at: <https://www.ncbi.nlm.nih.gov/pubmed/15675948>.

459. Renzi C, Mastroeni S, Passarelli F, et al. Factors associated with large cutaneous squamous cell carcinomas. *J Am Acad Dermatol* 2010;63:404-411. Available at: <https://www.ncbi.nlm.nih.gov/pubmed/20598396>.



460. Diehl J, Choi YM, Liang LJ, Chiu M. Association Between Mohs Surgery Wait Times and Surgical Defect Size in Patients With Squamous Cell or Basal Cell Carcinoma of the Skin. *Dermatol Surg* 2015;41:768-774. Available at: <http://www.ncbi.nlm.nih.gov/pubmed/26050214>.

461. Wollina U, Bayyoud Y, Kronert C, Nowak A. Giant epithelial malignancies (Basal cell carcinoma, squamous cell carcinoma): a series of 20 tumors from a single center. *J Cutan Aesthet Surg* 2012;5:12-19. Available at: <http://www.ncbi.nlm.nih.gov/pubmed/22557850>.

462. Renzi C, Mastroeni S, Mannooranparampil TJ, et al. Delay in diagnosis and treatment of squamous cell carcinoma of the skin. *Acta Derm Venereol* 2010;90:595-601. Available at: <https://www.ncbi.nlm.nih.gov/pubmed/21057742>.

463. Kakagia D, Trypsiannis G, Karanikas M, et al. Patient-related delay in presentation for cutaneous squamous cell carcinoma. A cross-sectional clinical study. *Onkologie* 2013;36:738-744. Available at: <https://www.ncbi.nlm.nih.gov/pubmed/24356565>.

464. Amber KT, Bloom R, Abyaneh MY, et al. Patient Factors and Their Association with Nonmelanoma Skin Cancer Morbidity and the Performance of Self-skin Exams: A Cross-Sectional Study. *J Clin Aesthet Dermatol* 2016;9:16-22. Available at: <https://www.ncbi.nlm.nih.gov/pubmed/27878058>.

465. Janda M, Youl P, Neale R, et al. Clinical skin examination outcomes after a video-based behavioral intervention: analysis from a randomized clinical trial. *JAMA Dermatol* 2014;150:372-379. Available at: <https://www.ncbi.nlm.nih.gov/pubmed/24553807>.

466. Renzi C, Mastroeni S, Mannooranparampil TJ, et al. Skin cancer knowledge and preventive behaviors among patients with a recent history of cutaneous squamous cell carcinoma. *Dermatology* 2008;217:74-80. Available at: <https://www.ncbi.nlm.nih.gov/pubmed/18424897>.

467. Firooz A, Amin-Nejad R, Bouzari N, et al. Sun protection in Iranian kidney transplant recipients: knowledge, attitude and practice. *J Eur Acad Dermatol Venereol* 2007;21:754-757. Available at: <https://www.ncbi.nlm.nih.gov/pubmed/17567302>.

468. Thompson SC, Jolley D, Marks R. Reduction of solar keratoses by regular sunscreen use. *N Engl J Med* 1993;329:1147-1151. Available at: <https://www.ncbi.nlm.nih.gov/pubmed/8377777>.

469. van der Pols JC, Williams GM, Pandeya N, et al. Prolonged prevention of squamous cell carcinoma of the skin by regular sunscreen use. *Cancer Epidemiol Biomarkers Prev* 2006;15:2546-2548. Available at: <http://www.ncbi.nlm.nih.gov/pubmed/17132769>.

470. Green A, Williams G, Neale R, et al. Daily sunscreen application and betacarotene supplementation in prevention of basal-cell and squamous-cell carcinomas of the skin: a randomised controlled trial. *Lancet* 1999;354:723-729. Available at: <http://www.ncbi.nlm.nih.gov/pubmed/10475183>.

471. Ulrich C, Jurgensen JS, Degen A, et al. Prevention of non-melanoma skin cancer in organ transplant patients by regular use of a sunscreen: a 24 months, prospective, case-control study. *Br J Dermatol* 2009;161 Suppl 3:78-84. Available at: <http://www.ncbi.nlm.nih.gov/pubmed/19775361>.

472. Fischer AH, Wang TS, Yenokyan G, et al. Sunburn and sun-protective behaviors among adults with and without previous nonmelanoma skin cancer (NMSC): A population-based study. *J Am Acad Dermatol* 2016;75:371-379 e375. Available at: <https://www.ncbi.nlm.nih.gov/pubmed/27198078>.

473. Wiznia L, Dai F, Chagpar AB. Do non-melanoma skin cancer survivors use tanning beds less often than the general public? *Dermatol Online J* 2016;22. Available at: <https://www.ncbi.nlm.nih.gov/pubmed/27617935>.



474. Girgis A, Sanson-Fisher RW, Watson A. A workplace intervention for increasing outdoor workers' use of solar protection. *Am J Public Health* 1994;84:77-81. Available at:

<https://www.ncbi.nlm.nih.gov/pubmed/8279616>.

475. Robinson JK, Friedewald JJ, Desai A, Gordon EJ. Response Across the Health-Literacy Spectrum of Kidney Transplant Recipients to a Sun-Protection Education Program Delivered on Tablet Computers: Randomized Controlled Trial. *JMIR Cancer* 2015;1:e8. Available at:

<https://www.ncbi.nlm.nih.gov/pubmed/28410176>.

476. Loescher LJ, Hansen C, Hepworth JT, et al. A preliminary study of a video intervention to inform solid organ transplant recipients about skin cancer. *Transplant Proc* 2013;45:3187-3189. Available at:

<https://www.ncbi.nlm.nih.gov/pubmed/23747188>.

477. Tavadia S, Dawn G, Payne C, et al. Skin-cancer awareness in Scottish cardiac transplant recipients. *Clin Exp Dermatol* 2006;31:354-357. Available at:

<https://www.ncbi.nlm.nih.gov/pubmed/16681574>.

478. Clowers-Webb HE, Christenson LJ, Phillips PK, et al. Educational outcomes regarding skin cancer in organ transplant recipients: Randomized intervention of intensive vs standard education. *Arch Dermatol* 2006;142:712-718. Available at:

<http://www.ncbi.nlm.nih.gov/pubmed/16785373>.

479. Kim NN, Boone SL, Ortiz S, et al. Squamous cell carcinoma in solid organ transplant recipients: influences on perception of risk and optimal time to provide education. *Arch Dermatol* 2009;145:1196-1197. Available at:

480. Robinson JK, Friedewald JJ, Desai A, Gordon EJ. A Randomized Controlled Trial of a Mobile Medical App for Kidney Transplant Recipients: Effect on Use of Sun Protection. *Transplant Direct* 2016;2. Available at:

<https://www.ncbi.nlm.nih.gov/pubmed/26900599>.

481. Goldenberg A, Nguyen BT, Jiang SI. Knowledge, understanding, and use of preventive strategies against nonmelanoma skin cancer in healthy and immunosuppressed individuals undergoing Mohs surgery. *Dermatol Surg* 2014;40:93-100. Available at:

<http://www.ncbi.nlm.nih.gov/pubmed/24354730>.

482. Borghi A, Corazza M, Battaglia Y, et al. What Is the Key to Improving Renal Transplant Recipients' Awareness of Skin Cancer Risk?

*Dermatology* 2016;232:715-720. Available at:

<https://www.ncbi.nlm.nih.gov/pubmed/28343227>.

483. Wohlk IM, Philipsen PA, Wulf HC. Factors associated with cessation of sunbed use among Danish women. *Photodermatol Photoimmunol Photomed* 2016;32:191-198. Available at:

<https://www.ncbi.nlm.nih.gov/pubmed/27084577>.

484. Ismail F, Mitchell L, Casabonne D, et al. Specialist dermatology clinics for organ transplant recipients significantly improve compliance with photoprotection and levels of skin cancer awareness. *Br J Dermatol* 2006;155:916-925. Available at:

<https://www.ncbi.nlm.nih.gov/pubmed/17034519>.

485. Seite S, Del Marmol V, Moyal D, Friedman AJ. Public primary and secondary skin cancer prevention, perceptions and knowledge: an international cross-sectional survey. *J Eur Acad Dermatol Venereol* 2017;31:815-820. Available at:

<https://www.ncbi.nlm.nih.gov/pubmed/28045207>.

486. Robinson JK, Turrisi R, Mallett KA, et al. Efficacy of an educational intervention with kidney transplant recipients to promote skin self-examination for squamous cell carcinoma detection. *Arch Dermatol* 2011;147:689-695. Available at:

<https://www.ncbi.nlm.nih.gov/pubmed/21339418>.

487. Gurudutt VV, Genden EM. Cutaneous squamous cell carcinoma of the head and neck. *J Skin Cancer* 2011;2011:502723. Available at:

<http://www.ncbi.nlm.nih.gov/pubmed/21461387>.



488. Veness MJ, Palme CE, Smith M, et al. Cutaneous head and neck squamous cell carcinoma metastatic to cervical lymph nodes (nonparotid): a better outcome with surgery and adjuvant radiotherapy. *Laryngoscope* 2003;113:1827-1833. Available at: <http://www.ncbi.nlm.nih.gov/pubmed/14520114>.

489. Hinerman RW, Indelicato DJ, Amdur RJ, et al. Cutaneous squamous cell carcinoma metastatic to parotid-area lymph nodes. *Laryngoscope* 2008;118:1989-1996. Available at: <https://www.ncbi.nlm.nih.gov/pubmed/18849863>.

490. Jol JA, van Velthuysen ML, Hilgers FJ, et al. Treatment results of regional metastasis from cutaneous head and neck squamous cell carcinoma. *Eur J Surg Oncol* 2003;29:81-86. Available at: <https://www.ncbi.nlm.nih.gov/pubmed/12559082>.

491. Audet N, Palme CE, Gullane PJ, et al. Cutaneous metastatic squamous cell carcinoma to the parotid gland: analysis and outcome. *Head Neck* 2004;26:727-732. Available at: <http://www.ncbi.nlm.nih.gov/pubmed/15287040>.

492. Khurana VG, Mentis DH, O'Brien CJ, et al. Parotid and neck metastases from cutaneous squamous cell carcinoma of the head and neck. *Am J Surg* 1995;170:446-450. Available at: <https://www.ncbi.nlm.nih.gov/pubmed/7485729>.

493. O'Brien CJ, McNeil EB, McMahon JD, et al. Significance of clinical stage, extent of surgery, and pathologic findings in metastatic cutaneous squamous carcinoma of the parotid gland. *Head Neck* 2002;24:417-422. Available at: <http://www.ncbi.nlm.nih.gov/pubmed/12001070>.

494. Forest VI, Clark JJ, Veness MJ, Milross C. N1S3: a revised staging system for head and neck cutaneous squamous cell carcinoma with lymph node metastases: results of 2 Australian Cancer Centers. *Cancer* 2010;116:1298-1304. Available at: <https://www.ncbi.nlm.nih.gov/pubmed/20052712>.

495. Chua MS, Veness MJ, Morgan G, et al. Parotid lymph-node metastases from cutaneous squamous-cell carcinomas: treatment outcome and prognostic factors following surgery and adjuvant radiotherapy. *Australas Radiol* 2002;46:174-179. Available at: <https://www.ncbi.nlm.nih.gov/pubmed/12060157>.

496. Dona E, Veness MJ, Cakir B, Morgan GJ. Metastatic cutaneous squamous cell carcinoma to the parotid: the role of surgery and adjuvant radiotherapy to achieve best outcome. *ANZ J Surg* 2003;73:692-696. Available at: <https://www.ncbi.nlm.nih.gov/pubmed/12956783>.

497. Veness MJ, Morgan GJ, Palme CE, Gebiski V. Surgery and adjuvant radiotherapy in patients with cutaneous head and neck squamous cell carcinoma metastatic to lymph nodes: combined treatment should be considered best practice. *Laryngoscope* 2005;115:870-875. Available at: <http://www.ncbi.nlm.nih.gov/pubmed/15867656>.

498. Kirke DN, Porceddu S, Wallwork BD, et al. Pathologic occult neck disease in patients with metastatic cutaneous squamous cell carcinoma to the parotid. *Otolaryngol Head Neck Surg* 2011;144:549-551. Available at: <http://www.ncbi.nlm.nih.gov/pubmed/21493233>.

499. Pramana A, Browne L, Graham PH. Metastatic cutaneous squamous cell carcinoma to parotid nodes: the role of bolus with adjuvant radiotherapy. *J Med Imaging Radiat Oncol* 2012;56:100-108. Available at: <https://www.ncbi.nlm.nih.gov/pubmed/22339753>.

500. Goh RY, Bova R, Fogarty GB. Cutaneous squamous cell carcinoma metastatic to parotid - analysis of prognostic factors and treatment outcome. *World J Surg Oncol* 2012;10:117. Available at: <http://www.ncbi.nlm.nih.gov/pubmed/22731750>.

501. Hirshoren N, Danne J, Dixon BJ, et al. Prognostic markers in metastatic cutaneous squamous cell carcinoma of the head and neck. *Head Neck* 2017;39:772-778. Available at: <https://www.ncbi.nlm.nih.gov/pubmed/28199044>.



502. Czerwonka L, De Santis RJ, Horowitz G, et al. Staging cutaneous squamous cell carcinoma metastases to the parotid gland. *Laryngoscope* 2017;127:2063-2069. Available at: <https://www.ncbi.nlm.nih.gov/pubmed/28295401>.

503. Peiffer N, Kutz JW, Jr., Myers LL, et al. Patterns of regional metastasis in advanced stage cutaneous squamous cell carcinoma of the auricle. *Otolaryngol Head Neck Surg* 2011;144:36-42. Available at: <http://www.ncbi.nlm.nih.gov/pubmed/21493384>.

504. Kraus DH, Carew JF, Harrison LB. Regional lymph node metastasis from cutaneous squamous cell carcinoma. *Arch Otolaryngol Head Neck Surg* 1998;124:582-587. Available at: <http://www.ncbi.nlm.nih.gov/pubmed/9604987>.

505. Givi B, Andersen PE, Diggs BS, et al. Outcome of patients treated surgically for lymph node metastases from cutaneous squamous cell carcinoma of the head and neck. *Head Neck* 2011;33:999-1004. Available at: <http://www.ncbi.nlm.nih.gov/pubmed/21284049>.

506. Sweeny L, Zimmerman T, Carroll WR, et al. Head and neck cutaneous squamous cell carcinoma requiring parotidectomy: prognostic indicators and treatment selection. *Otolaryngol Head Neck Surg* 2014;150:610-617. Available at: <https://www.ncbi.nlm.nih.gov/pubmed/24474713>.

507. Thom JJ, Moore EJ, Price DL, et al. The Role of Total Parotidectomy for Metastatic Cutaneous Squamous Cell Carcinoma and Malignant Melanoma. *JAMA Otolaryngol Head Neck Surg* 2014;140:548-554. Available at: <https://www.ncbi.nlm.nih.gov/pubmed/24722863>.

508. Amoils M, Lee CS, Sunwoo J, et al. Node-positive cutaneous squamous cell carcinoma of the head and neck: Survival, high-risk features, and adjuvant chemoradiotherapy outcomes. *Head Neck* 2017;39:881-885. Available at: <https://www.ncbi.nlm.nih.gov/pubmed/28252823>.

509. Cartei G, Cartei F, Interlandi G, et al. Oral 5-fluorouracil in squamous cell carcinoma of the skin in the aged. *Am J Clin Oncol* 2000;23:181-184. Available at: <https://www.ncbi.nlm.nih.gov/pubmed/10776981>.

510. Nakamura K, Okuyama R, Saida T, Uhara H. Platinum and anthracycline therapy for advanced cutaneous squamous cell carcinoma. *Int J Clin Oncol* 2013;18:506-509. Available at: <https://www.ncbi.nlm.nih.gov/pubmed/22534799>.

511. Jarkowski A, 3rd, Hare R, Loud P, et al. Systemic Therapy in Advanced Cutaneous Squamous Cell Carcinoma (CSCC): The Roswell Park Experience and a Review of the Literature. *Am J Clin Oncol* 2016;39:545-548. Available at: <https://www.ncbi.nlm.nih.gov/pubmed/24879468>.

512. Picard A, Pedeutour F, Peyrade F, et al. Association of Oncogenic Mutations in Patients With Advanced Cutaneous Squamous Cell Carcinomas Treated With Cetuximab. *JAMA Dermatol* 2017;153:291-298. Available at: <https://www.ncbi.nlm.nih.gov/pubmed/28259104>.

513. Holoye PY, Byers RM, Gard DA, et al. Combination chemotherapy of head and neck cancer. *Cancer* 1978;42:1661-1669. Available at: <https://www.ncbi.nlm.nih.gov/pubmed/81714>.

514. Nottage MK, Lin C, Hughes BG, et al. Prospective study of definitive chemoradiation in locally or regionally advanced squamous cell carcinoma of the skin. *Head Neck* 2017;39:679-683. Available at: <https://www.ncbi.nlm.nih.gov/pubmed/28032670>.

515. O'Bryan K, Sherman W, Niedt GW, et al. An evolving paradigm for the workup and management of high-risk cutaneous squamous cell carcinoma. *J Am Acad Dermatol* 2013;69:595-602 e591. Available at: <https://www.ncbi.nlm.nih.gov/pubmed/23871719>.

516. Preneau S, Rio E, Brocard A, et al. Efficacy of cetuximab in the treatment of squamous cell carcinoma. *J Dermatolog Treat* 2014;25:424-427. Available at: <http://www.ncbi.nlm.nih.gov/pubmed/23167307>.



517. Conen KL, Fischer N, Hofbauer GF, et al. Cetuximab in metastatic squamous cell cancer of the skin: a Swiss case series. *Dermatology* 2014;229:97-101. Available at:

<https://www.ncbi.nlm.nih.gov/pubmed/24923455>.

518. Foote MC, McGrath M, Guminski A, et al. Phase II study of single-agent panitumumab in patients with incurable cutaneous squamous cell carcinoma. *Ann Oncol* 2014;25:2047-2052. Available at:

<https://www.ncbi.nlm.nih.gov/pubmed/25091317>.

519. Trodello C, Pepper JP, Wong M, Wysong A. Cisplatin and Cetuximab Treatment for Metastatic Cutaneous Squamous Cell Carcinoma: A Systematic Review. *Dermatol Surg* 2017;43:40-49. Available at:

<https://www.ncbi.nlm.nih.gov/pubmed/27618393>.

520. Teramoto Y, Nakamura Y, Yamada K, Yamamoto A. Oral S-1 in advanced cutaneous squamous cell carcinoma. *J Dermatol* 2014;41:494-497. Available at: <https://www.ncbi.nlm.nih.gov/pubmed/24814954>.

521. Bossi P, Cavalieri S, Perrone F, et al. Efficacy and safety of single agent pan-HER inhibitor dacomitinib in locally advanced unresectable or metastatic skin squamous cell cancer (sSCC) [abstract]. *Journal of Clinical Oncology* 2017;35:Abstract 9543. Available at:

[http://ascopubs.org/doi/abs/10.1200/JCO.2017.35.15\\_suppl.9543](http://ascopubs.org/doi/abs/10.1200/JCO.2017.35.15_suppl.9543).

522. National Institutes of Health. Dasatinib in Treating Patients With Unresectable or Metastatic Squamous Cell Skin Cancer or RAI Stage 0-I Chronic Lymphocytic Leukemia. Available at:

<https://clinicaltrials.gov/ct2/show/record/NCT00563290>. Accessed Aug 28, 2017.

523. National Institutes of Health. Efficacy and Safety of Dacomitinib in the Treatment of Skin Squamous Cell Cancer. Available at:

<https://clinicaltrials.gov/ct2/show/record/NCT02268747>. Accessed Aug 28, 2017.

524. National Institutes of Health. Study of Erlotinib in the Treatment of Recurrent or Metastatic Cutaneous Squamous Cell Carcinoma (CSCC) of the Skin. Available at:

<https://clinicaltrials.gov/ct2/show/record/NCT01198028>. Accessed Aug 28, 2017.

525. Maubec E, Helfen S, Scheer-Senyarich I, et al. CARSKIN: Pembrolizumab as first line therapy in patients with unresectable cutaneous squamous cell carcinoma (cSCC) [abstract]. *Journal of Clinical Oncology* 2017;35:Abstract TPS9596. Available at:

[http://ascopubs.org/doi/abs/10.1200/JCO.2017.35.15\\_suppl.TPS9596](http://ascopubs.org/doi/abs/10.1200/JCO.2017.35.15_suppl.TPS9596).

526. Papadopoulos KP, Owonikoko TK, Johnson ML, et al. REGN2810: A fully human anti-PD-1 monoclonal antibody, for patients with unresectable locally advanced or metastatic cutaneous squamous cell carcinoma (CSCC)—Initial safety and efficacy from expansion cohorts (ECs) of phase I study [abstract]. *Journal of Clinical Oncology* 2017;35:Abstract 9503. Available at:

[http://ascopubs.org/doi/abs/10.1200/JCO.2017.35.15\\_suppl.9503](http://ascopubs.org/doi/abs/10.1200/JCO.2017.35.15_suppl.9503).

527. National Institutes of Health. Study for the Evaluation of Efficacy of Pembrolizumab (MK-3475) in Patients With Rare Tumors. Available at: <https://clinicaltrials.gov/ct2/show/record/NCT02721732>. Accessed Aug 28, 2017.

528. National Institutes of Health. Study of REGN2810 in Patients With Advanced Cutaneous Squamous Cell Carcinoma. Available at: <https://clinicaltrials.gov/ct2/show/record/NCT02760498>. Accessed Aug 28, 2017.

529. National Institutes of Health. Talimogene Laherparepvec and Nivolumab in Treating Patients With Refractory Lymphomas or Advanced or Refractory Non-melanoma Skin Cancers. Available at:

<https://clinicaltrials.gov/ct2/show/record/NCT02978625>. Accessed Aug 28, 2017.



530. National Institutes of Health. Cobimetinib and Atezolizumab in Advanced Rare Tumors. Available at: <https://clinicaltrials.gov/ct2/show/record/NCT03108131>. Accessed Aug 28, 2017.

531. Tran DC, Colevas AD, Chang AL. Follow-up on Programmed Cell Death 1 Inhibitor for Cutaneous Squamous Cell Carcinoma. *JAMA Dermatol* 2017;153:92-94. Available at: <https://www.ncbi.nlm.nih.gov/pubmed/27784038>.

532. Stevenson ML, Wang CQ, Abikhair M, et al. Expression of Programmed Cell Death Ligand in Cutaneous Squamous Cell Carcinoma and Treatment of Locally Advanced Disease With Pembrolizumab. *JAMA Dermatol* 2017;153:299-303. Available at: <https://www.ncbi.nlm.nih.gov/pubmed/28259107>.

533. Falchook GS, Leidner R, Stankevich E, et al. Responses of metastatic basal cell and cutaneous squamous cell carcinomas to anti-PD1 monoclonal antibody REGN2810. *J Immunother Cancer* 2016;4:70. Available at: <https://www.ncbi.nlm.nih.gov/pubmed/27879972>.

534. Day F, Kumar M, Fenton L, Gedye C. Durable Response of Metastatic Squamous Cell Carcinoma of the Skin to Ipilimumab Immunotherapy. *J Immunother* 2017;40:36-38. Available at: <https://www.ncbi.nlm.nih.gov/pubmed/27684455>.

535. Deinlein T, Lax SF, Schwarz T, et al. Rapid response of metastatic cutaneous squamous cell carcinoma to pembrolizumab in a patient with xeroderma pigmentosum: Case report and review of the literature. *Eur J Cancer* 2017;83:99-102. Available at: <https://www.ncbi.nlm.nih.gov/pubmed/28734147>.

536. Degache E, Crochet J, Simon N, et al. Major response to pembrolizumab in two patients with locally advanced cutaneous squamous cell carcinoma. *J Eur Acad Dermatol Venereol* 2017. Available at: <https://www.ncbi.nlm.nih.gov/pubmed/28557105>.

537. Chang AL, Kim J, Luciano R, et al. A Case Report of Unresectable Cutaneous Squamous Cell Carcinoma Responsive to Pembrolizumab, a Programmed Cell Death Protein 1 Inhibitor. *JAMA Dermatol* 2016;152:106-108. Available at: <https://www.ncbi.nlm.nih.gov/pubmed/26422398>.

538. Merck & Co., Inc. Prescribing information: KEYTRUDA® (pembrolizumab) injection, for intravenous use. 2017. Available at: [http://www.merck.com/product/usa/pi\\_circulars/k/keytruda/keytruda\\_pi.pdf](http://www.merck.com/product/usa/pi_circulars/k/keytruda/keytruda_pi.pdf). Accessed September 8, 2017.

539. Bristol-Myers Squibb Company. Prescribing information: OPDIVO (nivolumab) injection, for intravenous use. 2017. Available at: [http://packageinserts.bms.com/pi/pi\\_opdivo.pdf](http://packageinserts.bms.com/pi/pi_opdivo.pdf). Accessed Sept 8, 2017.

540. Ferris RL, Blumenschein G, Jr., Fayette J, et al. Nivolumab for Recurrent Squamous-Cell Carcinoma of the Head and Neck. *N Engl J Med* 2016;375:1856-1867. Available at: <https://www.ncbi.nlm.nih.gov/pubmed/27718784>.

541. Chow LQ, Haddad R, Gupta S, et al. Antitumor Activity of Pembrolizumab in Biomarker-Unselected Patients With Recurrent and/or Metastatic Head and Neck Squamous Cell Carcinoma: Results From the Phase Ib KEYNOTE-012 Expansion Cohort. *J Clin Oncol* 2016;34:3838-3845. Available at: <https://www.ncbi.nlm.nih.gov/pubmed/27646946>.

542. Seiwert TY, Burtness B, Mehra R, et al. Safety and clinical activity of pembrolizumab for treatment of recurrent or metastatic squamous cell carcinoma of the head and neck (KEYNOTE-012): an open-label, multicentre, phase 1b trial. *Lancet Oncol* 2016;17:956-965. Available at: <https://www.ncbi.nlm.nih.gov/pubmed/27247226>.

543. Neuburg M. Transplant-associated skin cancer: role of reducing immunosuppression. *J Natl Compr Canc Netw* 2007;5:541-549. Available at: <http://www.ncbi.nlm.nih.gov/pubmed/17509256>.



544. Shin DM, Maloney ME, Lippman SM. Follow-up and prevention (squamous cell carcinoma). In: Miller SJ, Maloney ME, eds. Cutaneous Oncology Pathophysiology, diagnosis, and management. Malden, MA: Blackwell Science; 1998.

A large, light gray circular graphic with a double-line border. Inside the circle, the text "Discussion update in progress" is written in a bold, sans-serif font, centered vertically and horizontally.

Discussion  
update in  
progress